RD
651
U58
f.6
Suppl.
1982

TUMORS of the CENTRAL NERVOUS SYSTEM

by

LUCIEN J. RUBINSTEIN, M.D.

Supplement



AFIP

ATLAS OF TUMOR PATHOLOGY

Supplement

TUMORS OF THE CENTRAL NERVOUS SYSTEM

Fascicle 6, Second Series

by

LUCIEN J. RUBINSTEIN, M.D.
Professor of Pathology
Director, Division of Neuropathology
University of Virginia School of Medicine
Charlottesville, Virginia 22908

Published by the
ARMED FORCES INSTITUTE OF PATHOLOGY
Washington, D.C.

Under the Auspices of
UNIVERSITIES ASSOCIATED FOR RESEARCH AND EDUCATION IN PATHOLOGY, INC.
Bethesda, Maryland
1982

Accepted for Publication
1982

For sale by the Armed Forces Institute of Pathology
Washington, D.C. 20306
ISSN 0160–6344

ATLAS OF TUMOR PATHOLOGY

Sponsored by

AMERICAN CANCER SOCIETY
ARMED FORCES INSTITUTE OF PATHOLOGY
NATIONAL CANCER INSTITUTE, NATIONAL INSTITUTES OF HEALTH
UNIVERSITIES ASSOCIATED FOR RESEARCH AND EDUCATION IN PATHOLOGY, INC.

EDITOR
WILLIAM H. HARTMANN, M.D.
Professor and Chairman, Department of Pathology
Vanderbilt University School of Medicine
Nashville, Tennessee 37232
Area Code 615 – 329-2541

COEDITOR
WILLIAM R. COWAN, COLONEL, USAF, MC
Armed Forces Institute of Pathology
Washington, D.C. 20306

EDITORIAL ADVISORY COMMITTEE

Harlan I. Firminger, M.D.	University of Colorado Medical Center Denver, Colorado 80220
David G. Freiman, M.D.	Harvard Medical School and Beth Israel Hospital Boston, Massachusetts 02215
Robert V. P. Hutter, M.D.	St. Barnabas Medical Center Livingston, New Jersey 07039
F. K. Mostofi, M.D.	Armed Forces Institute of Pathology Washington, D.C. 20306
Alan Rabson, M.D.	National Cancer Institute, National Institutes of Health Bethesda, Maryland 20205
Richard J. Reed, M.D.	Tulane University School of Medicine New Orleans, Louisiana 70112
Juan Rosai, M.D.	University of Minnesota Medical School Minneapolis, Minnesota 55455

EDITOR'S NOTE

This is the second Supplement to the Fascicles of the Second Series of the Atlas of Tumor Pathology. Although planning for a Third Series is under way, availability is as yet at some time in the future. Because some of the Fascicles of the current Series are ten or more years old and because of advances in diagnostic anatomic pathology, this Series of Supplements seems appropriate. We hope you find them useful.

Each Supplement will be written by the authors of the Fascicles of the Second Series and subject to the usual review practices of the Editorial Advisory Committee and the Editor. It is unlikely there will be a Supplement for each Fascicle. As always, your comments are invited.

William H. Hartmann, M.D.

Permission to use copyrighted illustrations has been granted by:

Churchill Livingstone:
Recent Advances in Neuropathology, 1979. For figures 370, 371, 373, 374.

W. B. Saunders Company:
Hum. Pathol. 12:441-448, 1981. For figure 372 and Table VI.

Supplement

TUMORS OF THE CENTRAL NERVOUS SYSTEM

Fascicle 6, Second Series

Contents

Page No.

Experimental Tumors of the Nervous System S-1
- Induction of Experimental Neural Tumors S-1
  - Resorptive N-Nitroso Compounds S-1
  - Oncogenic Viruses S-4
- Experimental Models for Embryonal Tumors of the Central Nervous System S-5
- Transplantation of Human Gliomas to Athymic Nude Mice S-6

Relationship of Angioblastic Meningioma to Hemangiopericytoma S-9
- Definition of the Problem S-9
- Electron Microscopic Observations S-9
- Variants of Angioblastic Meningioma S-11
- Reappraisal of the Problem S-11
- Clinical Implications S-12
- The Papillary Variant of Meningioma S-13

Cytologic Variants of Pineal Parenchymal Tumors S-15
- Pineoblastomas S-16
- Pineocytomas S-17
  - Divergent Differentiation in Pineocytomas S-17
  - Astrocytic Differentiation S-17
  - Neuronal Differentiation S-17
- Electron Microscopy S-18
- Clinical Implications S-20

Diagnostic Applicability of GFA Protein Immunoperoxidase Staining S-21
- GFA Protein S-21
- PAP Immunohistochemistry S-21
- Application to Central Nervous System Tumors S-21
- General Results S-22
- Interpretative Problems S-23
- Recent Observations and Possible Implications S-24

Index S-31

Supplement

TUMORS OF THE CENTRAL NERVOUS SYSTEM

EXPERIMENTAL TUMORS OF THE NERVOUS SYSTEM

The introduction, in 1965, to the N-nitroso compounds as neurotropic carcinogenic agents, mentioned on page 6 of the Fascicle, was a major landmark that inaugurated over the next 15 years a most fruitful and still developing period in experimental neurooncology. In the following pages an attempt will be made to summarize the salient contributions that have emerged from the main approaches employed today, with special reference to the correlations to be established between experimentally induced tumors of the central and peripheral nervous systems and their respective equivalents in man. For detailed accounts of these models, the reader is referred to several useful reviews published in the last few years (Swenberg; Bullard and Bigner; Lantos) and to the comprehensive monograph by Jänisch and Schreiber, revised and augmented by Bigner and Swenberg, which includes a bibliography of virtually all the literature published on the subject through 1976.

The four principal animal experimental methods used today for the in vivo study of tumors of the nervous system are as follows:

The Induction of Experimental Neural Tumors by Resorptive N-Nitroso Compounds

These compounds, which have the general formula

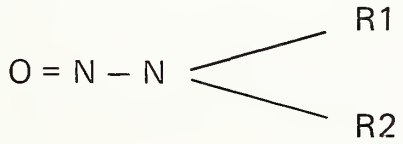

are, like other alkylating agents, mutagenic as well as carcinogenic. They share with other carcinogens and mutagens the property of being also teratogenic, especially when used in high concentration in early fetal life. One of their characteristics is their organ specificity, which is thought to be due largely to the action of their guiding (R2) radical, although it is well accepted that other factors such as the type of carcinogen, the dose concentration, the mode of application, and the strain and species of animals employed, also play an important role. In neurooncology, by far the most frequently used of these agents are the nitrosoureas, especially methylnitrosourea (MNU)

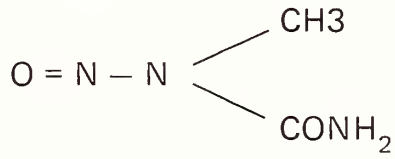

and ethylnitrosourea (ENU)

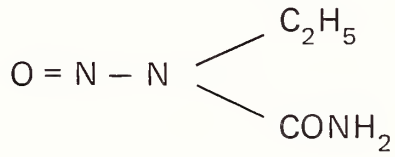

The marked instability of these compounds is compensated by the action of their guiding radical, in this instance urea, which is believed to facilitate their diffusion into the nervous system. The agents rapidly gain access to the central and peripheral nervous system tissues after transplacental injection

of the pregnant mother, or following intramuscular, intravenous, subcutaneous, or intraperitoneal injection, as well as after gastric absorption. They also act directly after intracerebral injection.

The molecular basis for the induction of malignancies by N-nitroso compounds is generally accepted to be alkylation, by the effector (R1) radical, of one or more bases of the DNA chain, resulting in anomalous base-pairing of the molecule. The neurocarcinogenicity of the nitrosoureas in the rat is suspected to be linked to a relative inability on the part of the target tissues, in this instance neural tissues, to excise O^6-alkylguanine from their DNA (Kleihues; Roberts). In transplacental carcinogenesis, the nervous system of the rat is maximally sensitive to neoplastic transformation during the last few days before birth and shortly thereafter. In the cerebral hemispheres, the migrating subependymal cells that are still cycling during that relatively late stage of neural development, namely glial cell precursors, are the ones that are selectively vulnerable to neoplastic transformation. The nitrosoureas have been shown to inhibit the mitotic activity of these proliferating cells: temporary cell cycle arrest occurs in or shortly before the S phase (Bosch). Presumably reentry into the cell cycle takes place long before the chemically induced alterations in the cellular macromolecules have been repaired. Such a mechanism would explain the rarity of neuronal tumors obtained with this experimental approach, since the overwhelming majority of neuronal precursor cells are no longer cycling by the time the developing nervous system has its first exposure to the carcinogenic agent. It also accounts for the frequency with which periventricular gliomas, often multifocal, are obtained after the transplacental injection of a single dose of ENU: these gliomas have presumably arisen from the subependymal plate (Pilkington and Lantos).

While different animal species, such as the hamster, the rabbit, and the dog, have been shown to be susceptible to the neurooncogenic agent, the mouse is relatively resistant (Wechsler et al.). The experimental animal of choice is the laboratory rat. To a large extent the chronologic pattern of tumor development, the incidence and the number of induced neoplasms, and the histologic type of neural tumors obtained are determined by the compound used, the animal species and the strain employed, the route of administration, and the dose of the carcinogen. A direct dose-response relationship has been determined (Swenberg et al., 1972b). There is a noteworthy tendency for multiple tumors, composed of either the same or different cell types, to appear in one animal following a single exposure to the agent. Multicentric foci of microscopic neoplastic transformation (microtumors) are frequent.

There is a characteristic time pattern of tumor development. Malignant schwannomas originating in the trigeminal ganglion tend to appear first, approximately 200 days after transplacental injection of ENU, and 265 days after a single injection of ENU in the neonate. The peak incidence of malignant schwannomas of the spinal nerve roots and of peripheral nerves follows shortly after. Most intracerebral and spinal gliomas make their appearance approximately 300 days after transplacental injection of ENU and 400 days after subcutaneous injection of the same compound in the neonate. Multiple periventricular subependymal gliomas have the longest induction time, approximately 415 days.

Repeated intravenous injection of MNU in young adult rats produces neural tumors in almost 100 percent of animals (Swenberg et al., 1972a). A single low intravenous dose of ENU at the 15th to 18th day of gestation in the pregnant dam, considerably lower than that needed to produce tumors in the adult, results in a virtual 100 percent incidence of neurogenic tumors in the offspring. In vitro transformation and tumorigenicity of fetal cerebral cells cultured at various time intervals after such a single injection have been demonstrated to occur during the latent period of carcinogenicity (Laerum et al.; Roscoe; Yoshida et al.).

In the central nervous system, the tumors obtained are almost all gliomas that involve both the brain and the spinal cord. Neuronal tumors have been reported only exceptionally. Exceptional also are cerebellar medulloblastomas, only a few of which have been obtained in the mouse (Searle and Jones), despite the marked vulnerability of the proliferating cells of the fetal external cerebellar granular layer to the cytotoxic action of nitrosoureas (Bosch et al.). The tumors are often of mixed cell type, and their various cellular elements cannot always be identified with precision. The most frequent type of pure glioma produced in this model is the oligodendroglioma, although good examples of astrocytoma may also be obtained (Sipe et al.). These animal gliomas virtually never show the classic histologic picture of glioblastoma seen in man.

In the peripheral nervous system, the most frequently induced tumors are schwannomas, which show various degrees of anaplasia depending on the compound used, the technic of administration, and the strain. Usually, the more anaplastic tumors are obtained following transplacental ENU injection in Sprague-Dawley or Long-Evans rats, whereas repeated intravenous injections of MNU in Fischer rats result in relatively more differentiated schwannomas. The most frequent site of malignant schwannoma induction is the trigeminal nerve root, followed by any of the spinal nerve roots. The origin of these tumors from neoplastic, transformed Schwann cells, even when most anaplastic, has been clearly established by electron microscopy of the early tumors. It is evident from their preferential localization and their biologic features that these experimental schwannomas in the rat differ greatly from their spontaneously occurring neoplastic equivalents in man.

The use of resorptive N-nitroso compounds as neurocarcinogens has led to many experimental extensions, including serial tumor transplantation; the evaluation of tumor response to radiation and antineoplastic chemotherapeutic agents; the in vitro behavior of neoplastic cells maintained in cell, tissue, and organ culture; the modulation, both in vivo and in vitro, of their morphologic and biochemical differentiating capabilities following pharmacologic manipulation of their environment; and the production of pure tumor cell lines following cloning procedures (Pfeiffer et al.). Several of these lines have been established and characterized in different laboratories (Ko et al.; Davaki and Lantos; Spence and Coates; Stavrou et al.), but the most extensively studied is the C-6 glioma, a line of cells cloned from an MNU-induced rat glioma (Benda et al.). The C-6 line has been widely used as a system for the investigation of the composition and function of glia; for the presence of specific surface antigens; its response to antimetabolites and vitamin depletion; the

presence of various enzymes implicated in active transport and cyclic AMP metabolism; its potential in cell hybridization experiments; its ability to release nerve growth factor; and its capacity to synthesize protein and enzyme markers specific for glial cells. Morphologically, the line represents a poorly differentiated glial cell type with the potential to differentiate structurally and, in certain well defined conditions, biochemically into astrocytes, with the production of glial fibrillary acidic protein (Bissell et al.) and of glutamine synthetase (Parker et al.), but is also endowed with the ability of synthesizing cyclic nucleotide phosphohydrolase, an enzyme marker for oligodendrocytes. Its diverse morphologic and biochemical modulations can be controlled and manipulated by in vitro exposure to various hormones and putative inducers, such as cyclic AMP or prostaglandin.

The Induction of Neural Tumors with Oncogenic Viruses

Earlier work using RNA tumor viruses, in particular the Rous avian sarcoma virus (RSV), has been summarized on page 6 of the Fascicle. Subsequent work with RSV has been largely confirmatory. The gliomas obtained in dogs after the neonatal intracerebral injection of the Schmidt-Ruppin strain of the virus (Haguenau et al.) are identical with the pilocytic astrocytomas of juvenile type encountered in man (see figs. 14 and 15). As in the case of gliomas induced with nitrosourea, the tumors often favor the region of the subependymal plate in the cerebral hemispheres (Vick et al.). In the rat, and in contrast to the gliomas induced with N-nitroso compounds, the most frequent glial neoplasm is the astrocytoma. The tumors obtained following the inoculation of the Bratislava 77 strain of RSV in Fischer rats are indistinguishable from the various grades of cerebral astrocytoma encountered in man (Copeland et al.). Glioblastomas are also produced following the inoculation of either the avian or the murine sarcoma virus (Yung et al.).

Among the DNA tumor viruses that are known to produce neural tumors after intracerebral injection, two have attracted attention in recent years. The human adenovirus type 12 is of interest because of its affinity for primitive neuronal cells when injected into hamsters or rats (Mukai). When the virus is introduced intracerebrally, neuroblastomas are obtained; intraocular injection results in the production of retinoblastomas; multicentric visceral or subcutaneous neuroblastomas are induced when the virus is respectively injected intraperitoneally or subcutaneously (Nakajima and Mukai).

Another neurooncogenic virus of interest is the JC strain of human polyoma virus known to cause progressive multifocal leukoencephalopathy. Intracerebral or subcutaneous injection of this virus in neonatal Syrian hamsters results in the production of a high incidence of cerebellar medulloblastomas that are often multifocal and appear to originate from the internal granular neurons (ZuRhein and Varakis). However, the transformed cells in this instance are likely to be those of the fetal external granular layer before they reach their terminal destination in the internal granular layer. This hypothesis is plausible because the outer zone of the external granular layer in the cerebellum shows a high mitotic index at the time of inoculation of the virus, and the cells of that layer retain their mitotic activity in the course of their

inward migration. Another noteworthy tumor obtained by the same workers with the same technic is an experimental pineocytoma (Varakis and ZuRhein). Biochemical differentiation in this tumor has been demonstrated by Quay and associates, who found, in the homogenates, various levels of hydroxy-indole-0-methyltransferase, which is required for the synthesis of the hormone melatonin. Intraocular injection of the JC strain of human polyoma virus in neonatal hamsters has resulted in the production of visceral neuroblastomas (Varakis et al.). The adenovirus type 12 and the JC strain of human polyoma virus are therefore of special interest because, unlike most central neural tumors obtained with alkylating agents or with RNA tumor viruses (which are comparable to human gliomas with varying degrees of glial differentiation), many of the tumors they produce are primitive neuroepithelial neoplasms. However, glioblastomas have also been induced by the inoculation of the JC virus into the hamster and in a nonhuman primate (London et al.).

A good deal of tumor-type specificity is therefore achieved by the local injection of these different oncogenic viruses.

Experimental Models for Embryonal Tumors of the Central Nervous System and for the Expression of Divergent Differentiation

In addition to the primitive neuroepithelial tumors obtained with some of the DNA oncogenic viruses, a promising model for the study of divergent neuroepithelial differentiation in embryonal tumors is a transplantable mouse teratoma, of which various cell lines are available. This experimental tumor was obtained following the grafting of pregastrulation embryos into the testis or beneath the renal capsule of susceptible inbred strains of mice. The teratomas are multipotential and malignant, but the progeny of the undifferentiated stem cells in these tumors, which develop either as ascitic or as solid implants, differentiate into derivatives of the three classic germ layers.

The solid tumors obtained from these lines contain a high percentage of neuroepithelial cells. In particular the OTT-6050 teratoma has been extensively analyzed in regard to the various stages of neuroepithelial differentiation that it demonstrates (Herman and VandenBerg). It provides valid histologic equivalents to the normal stages of neurocytogenesis of the developing avian and mammalian central nervous systems and to most of the embryonal tumors illustrated in the Fascicle (see figs. 126–129, 133, 134, 138, 169, 171). The suitability of this animal tumor model for the study of neuronal differentiation has been confirmed by the presence of significant concentrations of serotonin, cyclic AMP, and a number of enzymes involved in the metabolism of biogenic amines and acetylcholine (Orenberg et al.). Brain-associated cell surface membrane antigens have also been demonstrated on the differentiating neuroepithelial component of the teratoma by immunofluorescence (VandenBerg et al., 1977) and by immunoperoxidase (Ramsay et al.).

Elimination of differentiated non-neural elements has been obtained with this model, with the production of transplantable tumors in which the cells were restricted to undifferentiated stem cells and their neuroepithelial derivatives, which exhibited divergent glial and neuronal differentiation (Damjanov et al.; VandenBerg et al., 1981).

The potential significance of the mouse teratoma model extends beyond its narrow relevance to the study of embryonal tumors of the central nervous system by virtue of the fact that it illustrates the concept that faulty expression of developmentally relevant cellular genes, whether due to mutational, viral, or other causes, may underlie all forms of neoplasia and that the genes involved could be any of the ordinary genes involved in cell growth and differentiation (Mintz and Fleischman).

The Transplantation of Human Gliomas and their Cell Lines to Athymic Nude Mice

The heterografting of human cerebral tumors in animals, briefly discussed on pages 14 and 15 of the Fascicle, took a major forward stride with the introduction of the genetically thymus-deficient, or "nude" athymic mouse. Several reports from different laboratories have recently documented the successful establishment and maintenance of human gliomas, obtained from surgical specimens or from glioma cell lines, into the subcutaneous tissues or the brain of this immune-deficient host (Bradley et al.; Shapiro et al.; Bullard and Bigner; Yamashita et al.; Jones et al.; Horten et al.). The technical success and the apparent histopathologic validity of the model suggest that it might have potential for the evaluation of growth parameters and chemotherapeutic response of human gliomas. However, there is also evidence that cellular subpopulations from the original tumors may be preferentially selected for growth in the heterotransplants, and clinical inferences will therefore have to be drawn with caution.

References

Benda, P., Someda, K., Messer, J., and Sweet, W. H. Morphological and immunochemical studies of rat glial tumors and clonal strains propagated in culture. J. Neurosurg. 34:310-323, 1971.

Bissell, M. G., Rubinstein, L. J., Bignami, A., and Herman, M. M. Characteristics of the rat C-6 glioma maintained in organ culture systems. Production of glial fibrillary acidic protein in the absence of gliofibrillogenesis. Brain Res. 82:77-89, 1974.

Bosch, D. A. Chemical neuro-oncogenesis. An experimental study on some effects of N-methyl and N-ethyl-N nitrosourea on the developing nervous system of the rat. Acta Neurochir. 50:43-47, 1979.

_____, Gerrits, P. O., and Ebels, E. J. The cytotoxic effect of ethylnitrosourea and methylnitrosourea on the nervous system of the rat at different stages of development. Z. Krebsforsch. 77:308-318, 1972.

Bradley, N. J., Bloom, H. J. G., Davies, A. J. S., and Swift, S. M. Growth of human gliomas in immune-deficient mice: a possible model for pre-clinical therapy studies. Br. J. Cancer 38:263-272, 1978.

Bullard, D. E. and Bigner, D. D. Animal Models and Virus Induction of Tumours, pp. 51-84. In: Brain Tumours. Scientific Basis, Clinical Investigation and Current Therapy. Thomas, D. G. T. and Graham, D. I. (Eds.). London: Butterworths, 1980.

Copeland, D. D., Vogel, F. S., and Bigner, D. D. The induction of intracranial neoplasms by the inoculation of avian sarcoma virus in perinatal and adult rats. J. Neuropathol. Exp. Neurol. 34:340-358, 1975.

Damjanov, I., Solter, D., and Serman, D. Teratocarcinoma with the capacity for differentiation restricted to neuro-ectodermal tissue. Virchows Arch. [Cell Pathol.] 13:179-195, 1973.

Davaki, P. and Lantos, P. L. The development of brain tumours produced in rats by the intracerebral injection of neoplastic glial cells: a fine structural study. Neuropathol. Appl. Neurobiol. 7:49-61, 1981.

Haguenau, F., Rabotti, G. F., Lyon, G., and Moraillon, A. Gliomas induced by Rous sarcoma virus in the dog — an ultra-structural study. J. Natl. Cancer Inst. 46:539-559, 1971.

Herman, M. M. and VandenBerg, S. R. Neoplastic Neuroepithelial Differentiation in an Experimental Transplantable Teratoma, pp. 93-109. In: Cell Differentiation and Neoplasia, (30th Annual Symposium on Fundamental Cancer Research). Saunders, G. F. (Ed.). New York: Raven Press, 1978.

Horten, B. C., Basler, G. A., and Shapiro, W. R. Xenograft of human malignant glial tumors into brains of nude mice. A histopathological study. J. Neuropathol. Exp. Neurol. 40:493-511, 1981.

Jänisch, W. and Schreiber, D. Experimental Tumors of the Central Nervous System. First English Edition. Bigner, D. D. and Swenberg, J. A. (Eds.). Kalamazoo, MI: Upjohn Co., 1977.

Jones, T. R., Bigner, S. H., Schold, S. C., Jr., Eng, L. F., and Bigner, D. D. Anaplastic human gliomas in athymic mice. Morphology and glial fibrillary acidic protein expression. Am. J. Pathol. 105:316-327, 1981.

Kleihues, P. DNA Damage and Repair in Experimental Neurooncogenesis, pp. 161-178. In: Recent Advances in Neuropathology, No. 1. Smith, W. T. and Cavanagh, J. B. (Eds.). Edinburgh: Churchill Livingstone, 1979.

Ko, L., Koestner, A., and Wechsler, W. Characterization of cell cycle and biological parameters of transplantable glioma cell lines and clones. Acta Neuropathol. 51:107-111, 1980.

Laerum, O. D., Rajewsky, M. F., Schachner, M., Stavrou, D., Haglid, K. G., and Haugen, Å. Phenotypic properties of neoplastic cell lines developed from fetal rat brain cells in culture after exposure to ethylnitrosourea in vivo. Z. Krebsforsch. 89:273-295, 1977.

Lantos, P. L. Chemical Induction of Tumours in the Nervous System, pp. 85-108. In: Brain Tumours. Scientific Basis, Clinical Investigation and Current Therapy. Thomas, D. G. T. and Graham, D. I. (Eds.). London: Butterworths, 1980.

London, W. T., Houff, S. A., Madden, D. L., Fuccillo, D. A. et al. Brain tumors in owl monkeys inoculated with a human polyomavirus (JC virus). Science 201:1246-1249, 1978.

Mintz, B. and Fleischman, R. A. Teratocarcinomas and other neoplasms as developmental defects in gene expression. Adv. Cancer Res. 34:211-278, 1981.

Mukai, N. Human Adenovirus-induced Embryonic Neuronal Tumor Phenotype in Rodents, pp. 89-128. In: Progress in Neuropathology, Vol. III. Zimmerman, H. M. (Ed.). New York: Grune and Stratton, 1976.

Nakajima, T. and Mukai, N. Cell origin of human adenovirus type 12-induced subcutaneous tumor in Syrian hamsters. Acta Neuropathol. 45:187-194, 1979.

Orenberg, E. K., VandenBerg, S. R., Barchas, J. D., and Herman, M. M. Neurochemical studies in a mouse teratoma with neuroepithelial differentiation. Presence of cyclic AMP, serotonin and enzymes of the serotonergic, adrenergic and cholinergic systems. Brain Res. 101:273-281, 1976.

Parker, K. K., Norenberg, M. D., and Vernadakis, A. "Transdifferentiation" of C6 glial cells in culture. Science 208:179-181, 1980.

Pfeiffer, S. E., Betschart, B., Cook, J., Mancini, P., and Morris, R. Glial Cell Lines, pp. 287-346. In: Cell Tissue and Organ Cultures in Neurobiology. Fedoroff, S. and Hertz, L. (Eds.). New York: Academic Press, 1978.

Pilkington, G. J. and Lantos, P. L. The development of experimental brain tumours. A sequential light and electron microscope study of the subependymal plate. II. Microtumours. Acta Neuropathol. 45:177-185, 1979.

Quay, W. B., Ma, Y-H., Varakis, J. N., ZuRhein, G. M. et al. Modification of hydroxyindole-0-methyltransferase activity in experimental pineocytomas induced in hamsters by a human papovavirus (JC). J. Natl. Cancer Inst. 58:123-127, 1977.

Ramsay, P. B., VandenBerg, S. R., Eng, L. F., Herman, M. M., and Rubinstein, L. J. Immunologic recognition of cell surface antigens in normal mouse neural tissues and in neuroepithelial cells of the OTT-6050 mouse teratoma. A radiometric, gel electrophoretic and morphologic (immunofluorescence and immunoperoxidase) study. Acta Neuropathol. 56:214-224, 1982.

Roberts, J. J. Cellular responses to carcinogen-induced DNA damage and the role of DNA repair. Br. Med. Bull. 36:25-31, 1980.

Roscoe, J. P. In-vivo—in-vitro analysis of ethylnitrosourea-induced brain carcinogenesis in the rat. Br. Med. Bull. 36:33-38, 1980.

Searle, C. E. and Jones, E. L. Tumours of the nervous system in mice treated neonatally with N-ethyl-N-nitrosourea. Nature 240:559-560, 1972.

Shapiro, W. R., Basler, G. A., Chernik, N. L., and Posner, J. B. Human brain tumor transplantation into nude mice. J. Natl. Cancer Inst. 62:447-453, 1979.

Sipe, J. C., Rubinstein, L. J., Herman, M. M., and Bignami, A. Ethylnitrosourea-induced astrocytomas. Morphologic observations on rat tumors maintained in tissue and organ culture systems. Lab. Invest. 31:571-579, 1974.

Spence, A. M. and Coates, P. W. Scanning electron microscopy of cloned astrocytic lines derived from ethylnitrosourea-induced rat gliomas. Virchows Arch. [Cell Pathol.] 28:77-85, 1978.

Stavrou, D., Rieske, E., Anzil, A. P., Haglid, K. G., and Isenberg, G. Definition of a cell clone with astroglial characteristics derived from a chemically induced rabbit brain glioma. J. Neurol. Sci. 45:287-301, 1980.

Swenberg, J. A. Chemical Induction of Brain Tumors, pp. 85-99. In: Neoplasia in the Central Nervous System, Advances in Neurology, Vol. 15. Thompson, R. A. and Green, J. R. (Eds.). New York: Raven Press, 1976.

_____, Koestner, A., and Wechsler, W. The induction of tumors of the nervous system with intravenous methylnitrosourea. Lab. Invest. 26:74-85, 1972a.

_____, Koestner, A., Wechsler, W., and Denlinger, R. H. Quantitative aspects of transplacental tumor induction with ethylnitrosourea in rats. Cancer Res. 32:2656-2660, 1972b.

VandenBerg, S. R., Hickey, J. E., and Herman, M. M. Brain-associated cell surface antigens on neuroepithelial cells in a transplantable mouse teratoma. Acta Neuropathol. 39:281-287, 1977.

_____, Chatel, M., Griffiths, O. M., DeArmond, S. J., Pappas, C., and Herman, M. M. Neural differentiation in the OTT-6050 mouse teratoma. Production of a tumor fraction restricted to stem cells and neural cells after centrifugal elutriation. Virchows Arch. [Pathol. Anat.] 392:281-294, 1981.

Varakis, J. and ZuRhein, G. M. Experimental pineocytoma of the Syrian hamster induced by a human papovavirus (JC). A light and electron microscopic study. Acta Neuropathol. 35:243-264, 1976.

_____, ZuRhein, G. M., Padgett, B. L., and Walker, D. L. Induction of peripheral neuroblastomas in Syrian hamsters after injection as neonates with JC virus, a human polyoma virus. Cancer Res. 38:1718-1722, 1978.

Vick, N. A., Lin, M-J., and Bigner, D. D. The role of the subependymal plate in glial tumorigenesis. Acta Neuropathol. 40:63-71, 1977.

Wechsler, W., Rice, J. M., and Vesselinovitch, S. D. Transplacental and Neonatal Induction of Neurogenic Tumors in Mice: Comparison with Related Species and with Human Pediatric Neoplasms, pp. 219-226. In: Perinatal Carcinogenesis, Natl. Cancer Inst. Monogr. 51. Rice, J. M. (Ed.). Bethesda, MD: DHEW Publication No. (NIH) 79-1633, 1979.

Yamashita, M., Egami, H., Mannoji, H., Ohta, M., and Kitamura, K. Alternate culture and animal passage of human gliomas. Acta Neuropathol. 53:35-40, 1981.

Yoshida, J., Cravioto, H., and Ransohoff, J. In vitro transformation of fetal brain cells from CDF rats exposed in utero to N-ethyl-N-nitrosourea: morphologic and immunologic studies. J. Natl. Cancer Inst. 64:1231-1239, 1980.

Yung, W. K., Blank, N. K., and Vick, N. A. 'Glioblastoma.' Induction of a reproducible autochthonous tumor in rats with murine sarcoma virus. Neurology 26:76-83, 1976.

ZuRhein, G. M. and Varakis, J. N. Perinatal Induction of Medulloblastomas in Syrian Golden Hamsters by a Human Polyoma Virus (JC), pp. 205-208. In: Perinatal Carcinogenesis, Natl. Cancer Inst. Monogr. 51. Rice, J. M. (Ed.). Bethesda, MD: DHEW Publication No. (NIH) 79-1633, 1979.

RELATIONSHIP OF ANGIOBLASTIC MENINGIOMA TO HEMANGIOPERICYTOMA

The debate on the definition of the angioblastic meningioma and its identification with the hemangiopericytoma has gained momentum in recent years.

Definition of the Problem. It centers on three main issues:

(1) Whether the angioblastic meningioma should be conceived as a single clinical and morphologic entity, or as one that includes different histologic variants;

(2) If the second of these alternatives is correct, whether the distinction carries clinical implications;

(3) Whether the morphologic identity of the angioblastic meningioma with the hemangiopericytoma warrants the reclassification of all, or most, angioblastic meningiomas as hemangiopericytomas.

Electron Microscopic Evidence. While, as noted on page 182 of the Fascicle and in the caption of figure 196, some workers had already suggested on the basis of light microscopy that the angioblastic type of meningioma should be renamed hemangiopericytoma of the meninges, it is more specifically on the grounds of electron microscopic observations that the argument has been made (Popoff et al.; Choux et al., Peña). The fine structure of this tumor, illustrated in figures 370 and 371, shows indeed marked differences from that of the classic meningotheliomatous or transitional meningioma. The cells are plump, with blunt cytoplasmic edges. The complex intercytoplasmic digitations characteristic of other forms of meningioma (fig. 200) are absent; there are no conspicuous desmosomes. The cells often contain abundant filaments, measuring 9-10 nm. in diameter, that may displace the other organelles to the periphery of the cytoplasm (fig. 371). In places, the extracellular compartment is filled by electron-dense material that is generally recognized to be basement-membrane material and presumably represents the intercellular reticulin fiber network demonstrable by light microscopy (fig. 197, which is from the same case as fig. 196).

On the basis of these fine structural features, the cell of origin of the tumor has been suggested to be the pericyte, a perithelial cell whose existence in the blood vessel walls of the central nervous system is now well established. The additional claim has been made that, consistent with their derivation from pericytes, the tumor cells show smooth muscle differentiation, as evidenced by the condensation of focal filamentous aggregates, also termed dense bodies. It cannot be denied that, both in their light and electron microscopic aspects, many angioblastic meningiomas are identical with the hemangiopericytomas of the soft tissues. However, a well defined pericytoplasmic basal lamina, which is characteristic of the normal pericyte, is not seen in the central nervous system tumors.

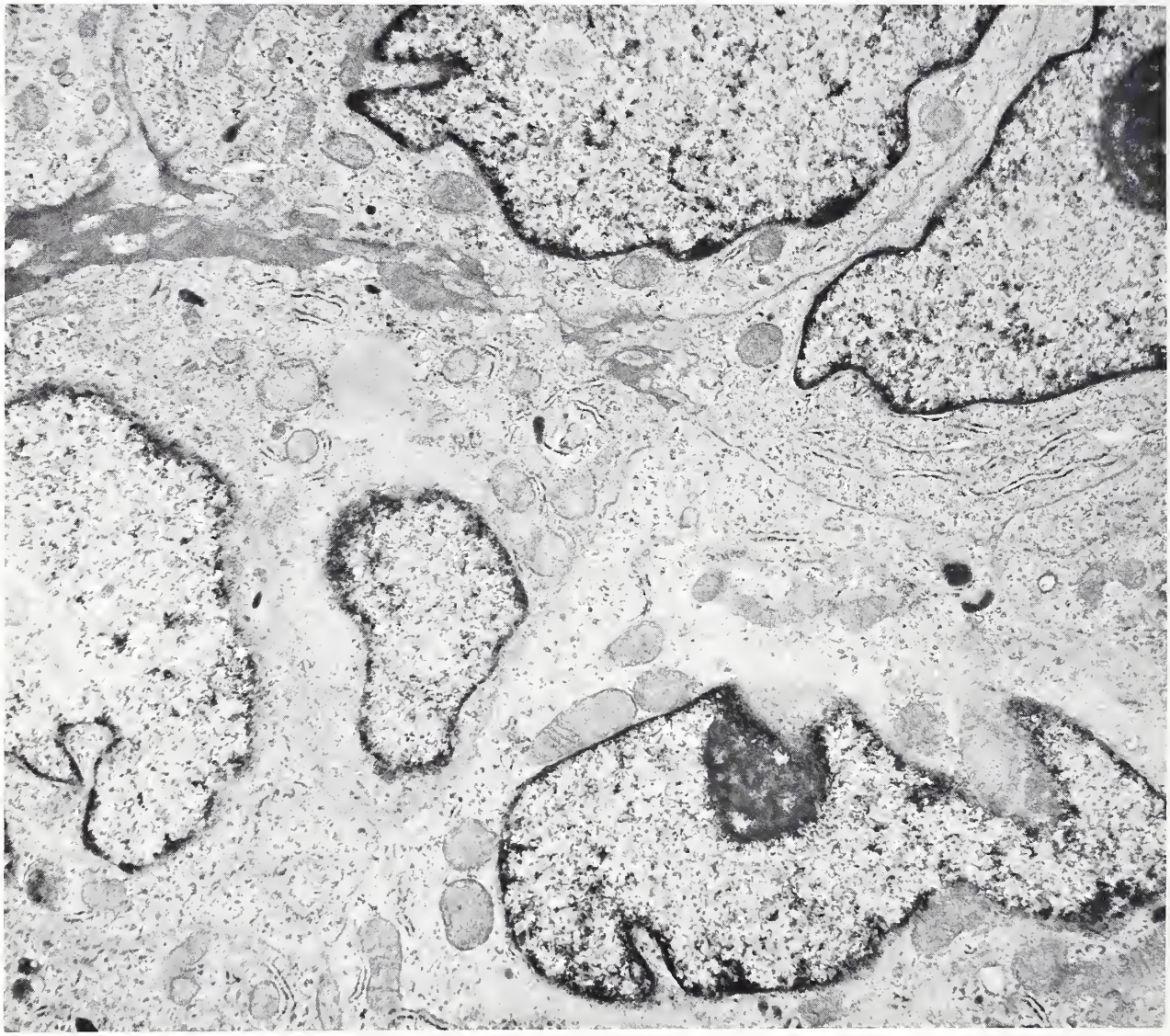

Figure 370
(Figures 370 and 371 from same case)
ANGIOBLASTIC MENINGIOMA OF HEMANGIOPERICYTIC TYPE

This electron micrograph, from a tumor maintained for eight days in organ culture, demonstrates plump cells with angulated cytoplasmic margins, devoid of the complex intercytoplasmic digitations that are characteristic of other forms of meningioma (see fig. 200). Electron-dense extracellular material, presumably basement-membrane material, is shown in the upper left portion of the electron micrograph. X6800. (Fig. 8.9A from Rubinstein, L. J. and Herman, M. M. Recent Advances in Human Neurooncology, Chapter 8. In: Recent Advances in Neuropathology. Smith, W. T. and Cavanagh, J. B. [Eds.]. Edinburgh, London, New York: Churchill Livingstone, 1979.)

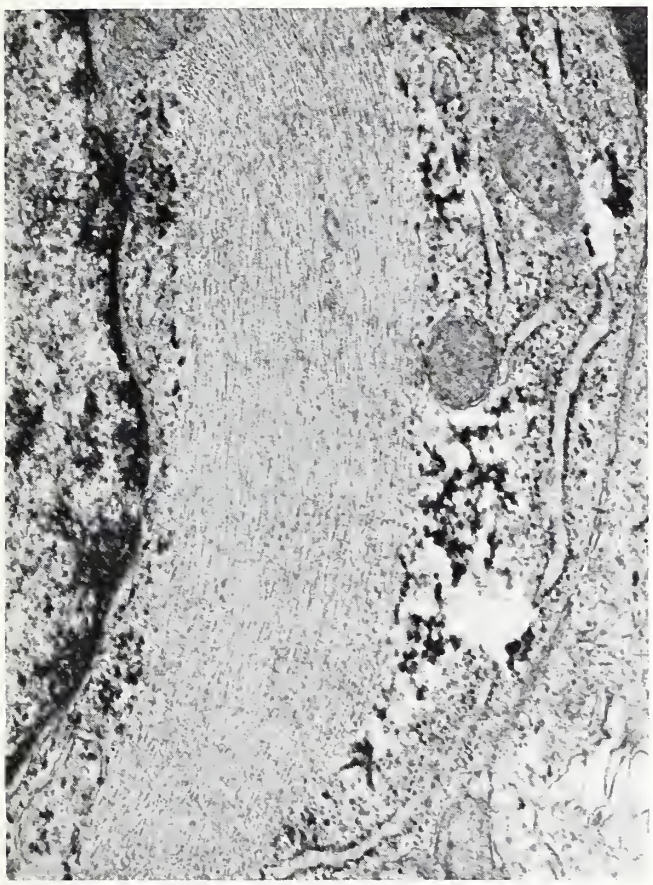

Figure 371
ANGIOBLASTIC MENINGIOMA
OF HEMANGIOPERICYTIC TYPE
This electron micrograph, taken from the same tumor as figure 370 after 22 days in organ culture, shows a compact bundle of cytoplasmic filaments measuring 10 nm. in diameter, adjacent to a tumor cell nucleus and displacing the other organelles. X27,300. (Fig. 8.9B from Rubinstein, L. J. and Herman, M. M. Recent Advances in Human Neurooncology, Chapter 8. In: Recent Advances in Neuropathology. Smith, W. T. and Cavanagh, J. B. [Eds.] Edinburgh, London, New York: Churchill Livingstone, 1979.)

Variants of Angioblastic Meningioma. The problem, on the other hand, is complicated by the fact that the angioblastic meningioma, after its original description by Bailey, Cushing, and Eisenhardt, was subsequently redefined by Cushing and Eisenhardt as including three variants. Of these, only variant 1, which was designated as incompletely differentiated, with mitoses, was equated with the angioblastic meningioma described in 1928. It is illustrated in figure 196. Variant 3, on the other hand, which was labelled angioblastoma, capillary or cellular, showed the microscopic features that were identical with those of the capillary hemangioblastoma, as illustrated in figure 195. Therefore, the discussion broached on page 181 of the Fascicle between the angioblastic meningioma and the capillary hemangioblastoma, in the course of which figures 195 and 248 are compared, applies to variant 3 only of the angioblastic meningioma of Cushing and Eisenhardt. Variant 2 consisted of a transitional form that included features both of variant 3 and of meningotheliomatous meningioma.

A major step in the resolution of this problem was taken by Pitkethly and associates, who, in their clinicopathologic study of 81 examples of angioblastic meningioma, simply separated this tumor into a hemangiopericytic (fig. 196) and a hemangioblastic (fig. 195) variant. We are essentially in agreement with this subdivision, which was determined not only by obvious histologic differences but also by a dissimilar clinical behavior, as the hemangiopericytic variant is characterized by considerably more aggressive growth, a more frequent and more rapid rate of recurrence, and a tendency to distant metastases, features that are not evident in the hemangioblastic variant.

Reappraisal of the Problem. In a further attempt to resolve some of these difficulties, we have reexamined the concept of the angioblastic meningioma in the context of a review of 79 meningeal and angioblastic tumors of the central nervous system in our material, with a comparison

of the electron microscopic features and in vitro evolution of two typical meningiomas with those of one intracranial hemangiopericytic example (Horten et al.). The three tumors were maintained both as conventional tissue culture explants on coverslips and in an organ culture system. While the great majority of the tumors in that study could readily be classified as either hemangiopericytomas or hemangioblastomas, several examples of transitional, or mixed, forms were noted bridging either of these variants with classic meningiomas, a finding that confirmed previous observations in the literature.

At the electron microscopic level, the two classic meningiomas and the hemangiopericytic neoplasm displayed a degree of morphologic overlap that was greater than had been recognized up till then. Both tumor types contained focal masses of dense intercellular filamentous or granular material resembling basement-membrane material. Both showed intracytoplasmic filaments measuring 10 nm. in diameter (figs. 200, 371). Also, the condensed filamentous aggregates regarded by some workers as evidence of smooth muscle differentiation in hemangiopericytoma (Popoff et al.; Peña) were present in a transitional meningioma: the specificity of this feature therefore became open to doubt. In summary, some of the electron microscopic criteria that had until then been assumed to separate the two tumor cell types in an unequivocal manner were not absolute.

The strongest in vitro evidence for the separation of the angioblastic meningioma from the hemangiopericytoma is the finding by Muller and Mealy that an angioblastic meningioma of hemangiopericytic type developed, after four days in culture, clear-cut whorls and imbrications of the tumor cells, an architectural feature that was entirely lacking in the original tissue preparations.

As a result of these various observations, we are of the view that the angioblastic meningioma deserves to be retained as an overall term encompassing the craniospinal hemangiopericytoma as one of its several variants, as well as the transitional forms that bridge the hemangiopericytoma, the hemangioblastoma, and the classic meningiomas. Perhaps the most satisfactory way of reconciling the divergent interpretations recalled in the previous paragraphs is to postulate that all these tumors share a common origin from polyblastic mesenchymal cells originating in, or derived from, the leptomeninges. While the validity of such a conclusion may admittedly continue to be a matter of debate from the conceptual point of view, we regard the term angioblastic meningioma of hemangiopericytic types as synonymous with craniospinal hemangiopericytoma, and clearly separate this variant from the hemangioblastic type of angioblastic meningioma.

Clinical Implications. From the clinical point of view, such a separation is essential. It is the hemangiopericytic variant that displays a significantly higher rate of recurrence than other forms of meningioma. Its recurrences also take place after a shorter period of time (Skullerud and Löken; Jellinger and Slowik). Mitotic figures are almost invariably present in the hemangiopericytic type (fig. 196) and are often abundant. Its tendency to develop remote metastases has become increasingly documented (Shuangshoti et al.; Petito and

Porro; Pitkethly et al.; Palacios and Azar-Kia). Of the eight meningiomas with extraneural metastases examined by me in the past 15 years, five were recurrent angioblastic meningiomas of this type, with cytologic features indicative of rapid growth. In the series of 85 meningiomas with distant metastases collected from the literature by Kepes, almost 30 percent were of the hemangiopericytic type.

The Papillary Variant of Meningioma. This rare malignant form (p. 186 of the Fascicle and figs. 202—204), on which a clinicopathologic survey of 17 examples in our material was reported (Ludwin et al.), may be combined with any of the various histologic variants of meningioma described on pages 175 through 184, but its association with the angioblastic form is notable. Twenty-nine percent of the papillary meningiomas in our series were of this type, which contrasts with the reported incidence of only 4 percent of angioblastic meningiomas among meningiomas as a whole (Pitkethly et al.).

References

Bailey, P., Cushing, H., and Eisenhardt, L. Angioblastic meningiomas. Arch. Pathol. 6:953-990, 1928.

Choux, R., Chrestian, M. A., Tripier, M. F., Gambarelli, D., Hassoun, J., and Toga, M. Hémangiopéricytome cérébral: Etude ultrastructurale d'un cas. J. Neurol. Sci. 28:361-371, 1976.

Cushing, H. and Eisenhardt, L. Meningiomas: Their Classification, Regional Behavior, Life History, and Surgical End Results. Springfield: Charles C Thomas, 1938.

Horten, B. C., Urich, H., Rubinstein, L. J., and Montague, S. R. The angioblastic meningioma: a reappraisal of a nosological problem. Light, electron microscopic, tissue, and organ culture observations. J. Neurol. Sci. 31:387-410, 1977.

Jellinger, K. and Slowik, F. Histological subtypes and prognostic problems in meningiomas. J. Neurol. 208:279-298, 1975.

Kepes, J. J. Meningiomas. Biology, Pathology, and Differential Diagnosis. New York: Masson, 1982.

Ludwin, S. K., Rubinstein, L. J., and Russell, D. S. Papillary meningioma: a malignant variant of meningioma. Cancer 36:1363-1373, 1975.

Muller, J. and Mealey, J. The use of tissue culture in differentiation between angioblastic meningioma and hemangiopericytoma. J. Neurosurg. 34:341-348, 1971.

Palacios, E. and Azar-Kia, B. Malignant metastasizing angioblastic meningiomas. J. Neurosurg. 42:185-188, 1975.

Peña, C. E. Intracranial hemangiopericytoma. Ultrastructural evidence of its leiomyoblastic differentiation. Acta Neuropathol. 33:279-284, 1971.

Petito, C. K. and Porro, R. S. Angioblastic meningioma with hepatic metastasis. J. Neurol. Neurosurg. Psychiatry 34:541-545, 1971.

Pitkethly, D. R., Hardman, J. M., Kempe, L. G., and Earle, K. M. Angioblastic meningiomas. Clinicopathologic study of 81 cases. J. Neurosurg. 32:539-544, 1970.

Popoff, N. A., Malinin, T. I., and Rosomoff, H. L. Fine structure of intracranial hemangiopericytoma and angiomatous meningioma. Cancer 34:1187-1197, 1974.

Shuangshoti, S., Hongsaprabhas, C., and Netsky, M. G. Metastasizing meningioma. Cancer 26:832-841, 1970.

Skullerud, K. and Löken, A. C. The prognosis in meningiomas. Acta Neuropathol. 29:337-344, 1974.

CYTOLOGIC VARIANTS OF PINEAL PARENCHYMAL TUMORS

As indicated on pages 279 and 280 of the Fascicle, the rarity of these tumors has until recently made it difficult to achieve a meaningful correlation between their histologic features and their biologic behavior. Later studies on relatively sizeable series now suggest that an accurate histologic classification of pineal neoplasms may have significant clinical and therapeutic implications. These series, together with a small number of recent, well detailed single case reports, have also contributed additional information on the capacity of these tumors to express divergent differentiation toward neuronal and neuroglial lines.

A series of 28 pineal parenchymal tumors, reported in greater detail elsewhere (Herrick and Rubinstein), has confirmed the separation of these neoplasms into two main categories: pineoblastomas, which are composed of uniform sheets of immature, poorly differentiated cells; and pineocytomas, in which the lobular architecture resembles that of the normal pineal gland. Both types may exhibit features of further cellular differentiation, and it is this capacity that seems to carry, in certain circumstances, important clinical meaning (Table VI). In the identification of this tumor material and in the demonstration of cellular differentiation considerable help was gained from a modification of the Achucárro-Hortega silver carbonate technic for pineal parenchymal cells applied to paraffin-embedded material, from the use of silver impregnation methods for the demonstration of axons and neurofibrils, from immunoperoxidase preparations demonstrating the presence of glial fibrillary acidic (GFA) protein in formalin-fixed, paraffin-embedded tissue sections (see page S-21), and from electron microscopy.

Table VI

CYTOLOGIC VARIANTS OF PINEAL PARENCHYMAL TUMORS AND THEIR BIOLOGIC BEHAVIOR*

Pineoblastomas	Malignant
With pineocytic differentiation	Malignant
With retinoblastomatous differentiation	Malignant
Pineocytomas	Malignant
With astrocytic differentiation	Malignant or benign
With neuronal differentiation	Benign
With neuronal and astrocytic differentiation ("gangliogliomas of pineal")	Benign

*From Rubinstein, L. J. Cytogenesis and differentiation of pineal parenchymal neoplasms. Hum. Pathol. 12:441-448, 1981.

PINEOBLASTOMAS

These tumors (11 cases in our series) are highly malignant, occur largely in children in the first or second decade, to a much lesser extent in young adults, virtually invariably metastasize in the cerebrospinal pathways and therefore behave as cerebellar medulloblastomas. Exceptionally they contain melanin pigment (Best; Herrick and Rubinstein, case 5). Rarely they may show bidirectional ganglionic and glial differentiation (Sobel et al.). Of great interest is the occasional development of Flexner-Wintersteiner rosettes and "fleurettes," characteristic of retinoblastomas (fig. 372; Stefanko and Manschot; Herrick and Rubinstein, case 11). A relationship between pineoblastoma and retinoblastoma has also been suggested by the reported concomitance of bilateral retinoblastomas and a separate pineoblastoma (Jakobiec et al., case 1). The function of the pineal gland in fishes and amphibians is chiefly that of a photoreceptor organ, while in mammals it plays an exclusively neurotransmitter role. The occurrence of retinoblastic features in human pineoblastoma is therefore a curious example of the ontogeny of an organ being recalled in its neoplastic development. Differentiation in these tumors is usually demonstrable at the primary site only, and does not seem to influence clinical behavior.

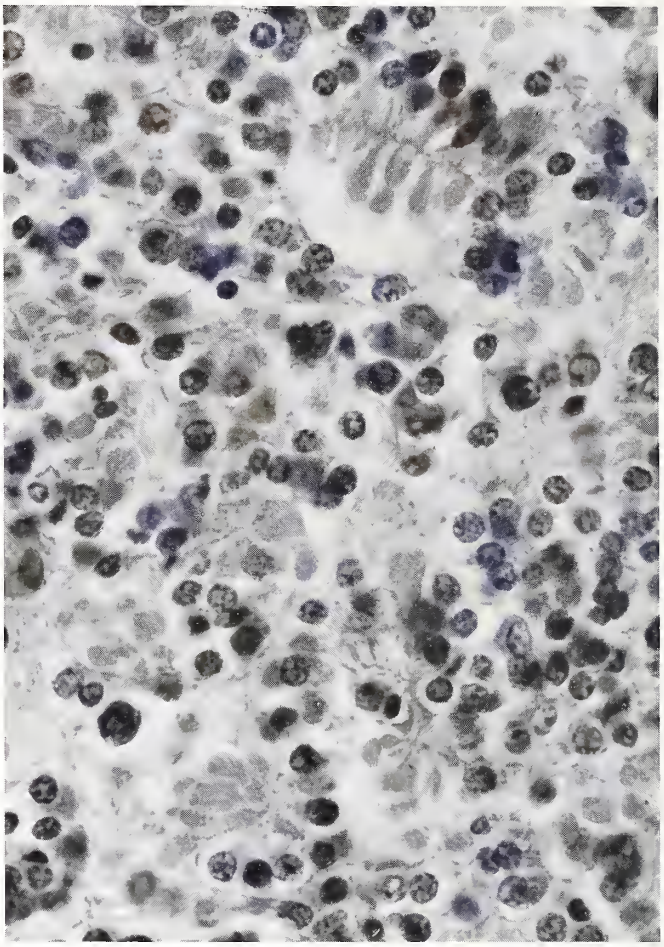

Figure 372
PINEOBLASTOMA
This field, from the primary site of a metastasizing pineoblastoma in a 3 year old boy, demonstrates fleurettes characteristic of retinoblastoma. X480. (Fig. 7 from Rubinstein, L. J. Cytogenesis and differentiation of pineal neoplasms. Hum. Pathol. 12:441-448, 1981).

The fine structure of this neoplasm has seldom been described. An example reported by Kline and associates in a 45 year old woman suggests analogies between the tumor cells and the photosensory cells in the pineal gland of lower vertebrates. The features include bulbous protrusions of the cytoplasm said to resemble the end-bulbs of the human fetal pineal gland, and giant club-shaped cilia with a 9+0 microtubular pattern characteristic of photoreceptor cells (in contrast to the 9+2 pattern typical of cilia associated with motility). The more differentiated features found in an experimental hamster pineocytoma and in human pineocytomas showing neuronal differentiation (see page S-18) were lacking.

PINEOCYTOMAS

These tumors, in which the lobular pattern of the pineal gland has been retained, are usually less cellular than pineoblastomas, but in the absence of further differentiation the distinction between the two may be difficult. Transitional or intermediate forms are frequent, and the pattern of both may coexist within the same example. Pineocytomas in which no further differentiation is demonstrable (7 examples in our series) occur at any age and may metastasize in the cerebrospinal pathways, but they do it less often than pineoblastomas. Their growth rate and capacity for local infiltration essentially equal those of pineoblastomas. None of the patients in our series with neoplasms that were classified either as pineoblastomas or as pineocytomas without further differentiation survived two years beyond the onset of symptoms. An exceptional example displaying prominent papillary features and the development of Flexner-Wintersteiner rosettes and fleurettes has been reported in an adult (Trojanowski et al.). We therefore regard these examples as malignant neoplasms (Table VI) and suggest that they should be treated in the same manner as pineoblastomas, that is, with vigorous radiation directed to the entire neuraxis.

A somewhat different taxonomic view has been adopted by Borit and associates in their review of 13 pineal parenchymal tumors. They likewise divided their material into pineoblastomas (8 cases) and pineocytomas (5 cases), but did not find any examples of pineocytoma with a lobulated pattern. They proposed that all these tumors should be regarded as pineoblastomas, and reserved the term pineocytoma for those examples only in which large rosettes are demonstrable (figs. 280, 281) and which we interpret as evincing neuronal differentiation (see below).

Divergent Differentiation in Pineocytomas. An impressive manifestation of pineocytoma cells is their capacity for differentiation into mature astrocytes or neurons, or both. Of the 17 pineocytomas in our series, 10 showed that feature. The majority exhibited divergent glial and ganglionic differentiation, that is, the characters of gangliogliomas, the first example of which was identified more than a decade ago (see p. 282 of the Fascicle) and is illustrated in figures 283–285.

Astrocytic Differentiation. Differentiation along purely astrocytic lines is uncommon; it was present in two cases only in our series. Of these, one behaved as a malignant neoplasm, with the development of widespread cerebrospinal metastases; the other was circumscribed and grew slowly over a period of eight years. Variations in the clinical evolution of pineal tumors with astrocytic differentiation should be expected in view of the wide variations in the behavior of astrocytic neoplasms in general. Rare examples have indeed been authenticated of glial tumors apparently having their primary origin in the pineal: these have ranged from a low-grade astrocytoma restricted to the gland and incidentally discovered at autopsy (Papasozomenos and Shapiro) to glioblastoma with leptomeningeal metastases (Norbut and Mendelow).

Neuronal Differentiation. Most pineocytomas showing further maturation demonstrated either pure neuronal or, more often, concomitant neuronal and astrocytic differentiation (7 tumors in our

series). These tumors are characterized by the presence of large rosettes of a unique appearance (fig. 280), which differ markedly from the more primitive Homer Wright rosettes found in medulloblastomas, in sympathetic and cerebral neuroblastomas, and in pineoblastomas (fig. 282). As demonstrated in figure 281, the centers of the rosettes contain delicate argyrophilic cell processes, often with a small bulbous terminal expansion. Adjacent microscopic fields frequently display large typical or polymorphic ganglion cells. These rosettes, which were labelled "pineocytomatous" by Borit and associates, are therefore to be interpreted as being formed by small mature neurons. This interpretation is supported by the fine structural features that have been reported in a few of these neoplasms.

Electron Microscopy. The demonstration, in such a case (Herrick and Rubinstein, case 27), of numerous closely packed neuritic processes filled with microtubules (fig. 373), of large numbers of dense-core

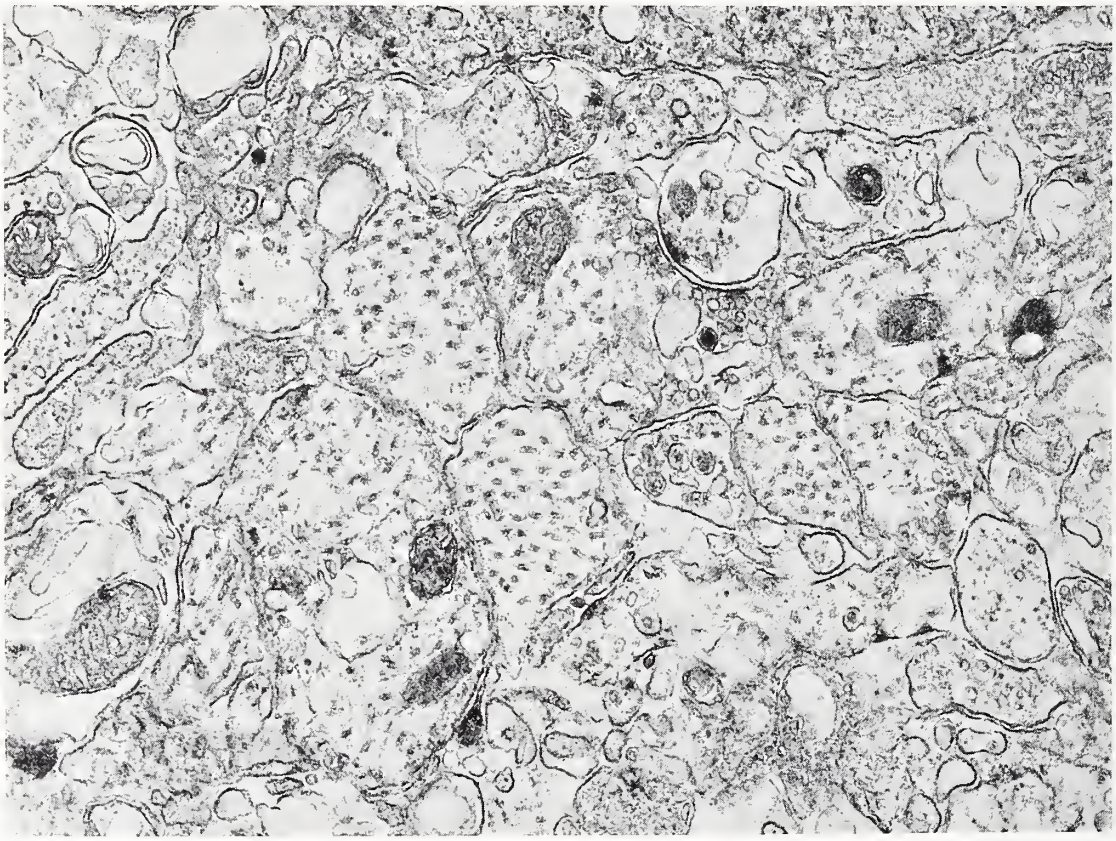

Figure 373
(Figures 373 and 374 from same case)
GANGLIONIC DIFFERENTIATION IN PINEOCYTOMA
This electron micrograph demonstrates tumor cell processes packed with microtubules. A synapse is present in the upper middle field. X23,000. (Fig. 8.12A from Rubinstein, L. J. and Herman, M. M. Recent Advances in Human Neurooncology, Chapter 8. In: Recent Advances in Neuropathology. Smith, W. T. and Cavanagh, J. B. [Eds.]. Edinburgh, London, New York: Churchill Livingstone, 1979.)

vesicles in the perikarya and processes of the tumor cells (fig. 374), and of synaptic complexes (fig. 374), unequivocally established its ganglionic nature. Structures resembling synaptic ribbons were also present. These features, which have been confirmed in two other examples of pineocytoma (Markesbery et al.), should be aligned with the electron microscopic observations of Varakis and ZuRhein on an experimental pineocytoma induced in a hamster by the JC strain of a human papovavirus. The fine structural appearances in the animal tumor recapitulated those of the developing photoreceptor cells of the retina, of the fetal pineal gland of the rat and hamster, and of pinealocytes of the newborn rat (Zimmerman and Tso). The presence, in the homogenates of seven of the experimental tumors, of various levels of hydroxy-indole-0-methyltransferase needed for the synthesis of melatonin (Quay et al.) exemplifies an attempt at biochemical differentiation in a neoplasm whose characteristics are essentially in agreement with our current concept of the pineal gland as a neurotransmitter organ.

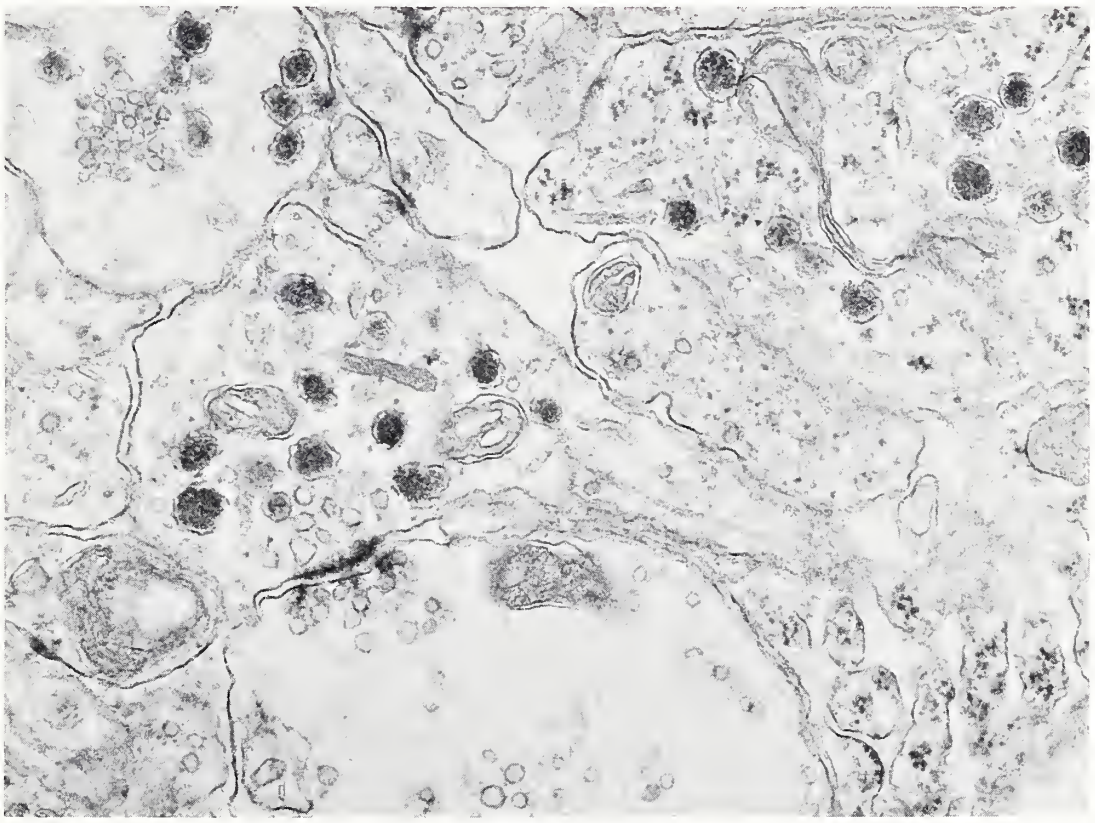

Figure 374
GANGLIONIC DIFFERENTIATION IN PINEOCYTOMA
This electron micrograph, taken from another field from the same tumor as figure 373, demonstrates numerous dense-core vesicles and one synapse. X34,000. (Fig. 8.12B from Rubinstein, L. J. and Herman, M. M. Recent Advances in Human Neurooncology, Chapter 8. In: Recent Advances in Neuropathology. Smith, W. T. and Cavanagh, J. B. [Eds.]. Edinburgh, London, New York: Churchill Livingstone, 1979).

Clinical Implications. All the pineocytomas with differentiating features in our series were discovered in adults. Those with neuronal, or neuronal and astrocytic, differentiation invariably remained localized and often had a prolonged clinical course suggestive of slow growth (Table VI), a correlation that has been independently confirmed (Borit et al.). None of these cases so far has developed distant metastases. It is in these patients therefore that tissue diagnosis is important for the appropriate therapeutic decision. Neoplasms with this degree of neuronal differentiation should not be expected to be radiosensitive, and therefore surgical excision, if feasible, should be the treatment of choice.

References

Best, P. V. A medulloblastoma-like tumour with melanin formation. J. Pathol. 110:109-111, 1973.

Borit, A., Blackwood, W., and Mair, W. G. P. The separation of pineocytoma from pineoblastoma. Cancer 45:1408-1418, 1980.

Herrick, M. K. and Rubinstein, L. J. The cytological differentiating potential of pineal parenchymal neoplasms (true pinealomas). A clinicopathological study of 28 tumors. Brain 102:289-320, 1979.

Jakobiec, F. A., Tso, M. O. M., Zimmerman, L. E., and Danis, P. Retinoblastoma and intracranial malignancy. Cancer 39:2048-2058, 1977.

Kline, K. T., Damjanov, I., Katz, S. M., and Schmidek, H. Pineoblastoma: an electron microscopic study. Cancer 44:1692-1699, 1979.

Markesbery, W. R., Haugh, R. M., and Young, A. B. Ultrastructure of pineal parenchymal neoplasms. Acta Neuropathol. 55:143-149, 1981.

Norbut, A. M. and Mendelow, H. Primary glioblastoma multiforme of the pineal region with leptomeningeal metastases. Cancer 47:592-596, 1981.

Papasozomenos, S. and Shapiro, S. Pineal astrocytoma. Report of a case confined to the epiphysis, with immunocytochemical and electron microscopic study. Cancer 47:99-103, 1981.

Quay, W. B., Ma, Y-H., Varakis, J. N., ZuRhein, G. M., Padgett, B. L., and Walker, D. L. Modification of hydroxyindole-0-methyltransferase activity in experimental pineocytomas induced in hamsters by a human papovavirus (JC). J. Natl. Cancer Inst. 58:123-127, 1977.

Sobel, R. A., Trice, J. E., Nielsen, S. L., and Ellis, W. G. Pineoblastoma with ganglionic and glial differentiation. Report of two cases. Acta Neuropathol. 55:243-246, 1981.

Stefanko, S. Z. and Manschot, W. A. Pinealoblastoma with retinoblastomatous differentiation. Brain 102:321-332, 1979.

Trojanowski, J. Q., Tascos, N. A., and Rorke, L. B. Malignant pineocytoma with prominent papillary features. Cancer (In press.)

Varakis, J. N. and ZuRhein, G. M. Experimental pineocytoma of the Syrian hamster induced by a human papovavirus (JC). A light and electron microscopic study. Acta Neuropathol. 35:243-264, 1976.

Zimmerman, B. L. and Tso, M. O. M. Morphologic evidence of photoreceptor differentiation of pinealocytes in the neonatal rat. J. Cell Biol. 66:60-75, 1975.

DIAGNOSTIC APPLICABILITY OF GFA PROTEIN IMMUNOPEROXIDASE STAINING

GFA Protein. Glial fibrillary acidic (GFA) protein, which currently is widely used as a cytoplasmic antigenic marker for the study of normal, developing, and pathologically altered glial cells, was originally isolated by aqueous extraction from old fibril-rich plaques of a human case of multiple sclerosis and purified by ammonium sulfate precipitation, isoelectric precipitation, and preparative polyacrylamide gel electrophoresis. Specific immunofluorescence readily localized it to fibrillary astrocytes. It is found in a wide range of animal species. The protein, which in the human has been estimated by gel electrophoresis to have a molecular weight of 48,000 ± 2,000 daltons, contains relatively large amounts of aspartic and glutamic acid, alanine, leucine, and arginine. There is mounting evidence that it is the chemical subunit of the 8-10 nm-sized intracytoplasmic filaments characteristic of astrocytic glial cells. Comprehensive reviews on its biochemical properties, on its relationship to other neural proteins, and on its putative role in normal and pathologic gliogenesis have been published by Eng and by Bignami and his colleagues.

PAP Immunohistochemistry. The advent of the peroxidase-antiperoxidase (PAP) immunohistochemical technic of Sternberger, the demonstration of its applicability to formalin-fixed paraffin-embedded tissues, and the availability of highly specific antiserum to purified GFA protein have led in recent years to a major advance in the more precise identification of diagnostically difficult tumors of the central nervous system. Details of the staining method, which can be undertaken in any reasonably equipped histology laboratory and for which the reagents are now all available commercially, will be found in the report by Eng and Rubinstein. Examples illustrating the results obtained are shown in plate XVI.

Applications to Central Nervous System Tumors. The advantages of the technic, which permits the GFA protein antigen to be directly visualized at the cell level in routinely processed preparations and therefore allows prospective and retrospective surveys of all available paraffin-embedded tissues, are evident. As reviewed by DeArmond and associates, several reports from different laboratories, based on a large and varied human tumor material, have rapidly established the immunoperoxidase method for GFA protein as the method of choice for the resolution of some of the more taxing problems of brain tumor diagnosis. Several of the questions that the application of this technic is currently raising on the staining affinities of nonneoplastic and neoplastic cells of the central nervous system have been discussed in detail in the progress report by DeArmond and colleagues. The salient conclusions emerging from the various studies to date may be summarized as follows.

General Results. (1) Neoplastic (pl. XVI-B) as well as reactive astrocytes (pl. XVI-A) show a markedly positive reaction. The extent of the reaction is inversely proportional to the anaplastic character of the tumor. Thus glioblastomas and malignant astrocytomas demonstrate positivity of neoplastic cells in the more differentiated astrocytic areas only (pl. XVI-B). Medulloblastomas, in which the overwhelming majority of the tumor cells are negative, may show in a number of cases positive tumor cells arranged either singly or in small clusters, indicating focal astrocytic differentiation (Palmer et al.; Mannoji et al.).

(2) In mixed tumors of the central nervous system, the method permits immediate distinction between astrocytic and nonastrocytic neoplastic glial elements in the case of mixed astrocytomas and oligodendrogliomas (pl. XVI-D), between glial and neuronal elements in the case of gangliogliomas, and between glial and mesenchymal neoplastic elements in the case of mixed gliomas and sarcomas (pl. XVI-E).

(3) Nonastrocytic tumor cells that have the capacity to form glial fibers, as in ependymomas, are therefore often, although not invariably, positive (pl. XVI-G). However, the demonstration of GFA protein by immunoperoxidase does not always correlate with the presence of glial fibers as revealed by classic neurohistologic stains for glia (the Holzer crystal violet stain or Mallory's phosphotungstic acid hematoxylin). Thus the astroblastoma (see p. 50 of the Fascicle and fig. 31), a tumor of astrocytic lineage in which neuroglial fibrils are seldom demonstrable by traditional neurohistologic technics, shows an intense GFA protein-positive reaction of the neoplastic cells, particularly in those that form perivascular pseudorosettes (pl. XVI-C).

(4) The method is particularly valuable for the recognition of glioma cells that extensively invade the leptomeninges (figs. 24, 25, 56; pl. II-C) and for establishing the identity of gliomas metastasizing to extraneural sites. A difficult diagnostic problem caused by the production of an abundant fibrous connective tissue stroma in response to glial tumor invasion (see pp. 43, 68, and 150 of the Fascicle) may be resolved by a positive GFA protein immunoperoxidase stain (pl. XVI-F).

(5) It facilitates the exclusion of nonglial neoplasms, such as alveolar soft part sarcomas, which may superficially resemble certain forms of astrocytoma with conventional stains.

(6) A consistent positive correlation can be demonstrated in the results obtained on the same material with the immunoperoxidase method and the indirect immunofluorescence reaction performed on unfixed frozen tissue sections (Velasco et al.)

(7) The localization of GFA protein in cerebral tumors by morphologic methods has been confirmed by quantitative determinations of the protein in various in vivo and in vitro systems, using different electrophoretic, immunodiffusion and immunoradiometric technics.

In summary, early studies have established that a positive reaction for GFA protein is demonstrable in the following tumors: astrocytomas, astroblastomas, glioblastomas (the more differentiated areas), ependymomas, subependymomas, and the astrocytic cells of mixed central nervous system neoplasms. A negative reaction to

GFA protein is found in primitive neuroepithelial cells, ganglion cells, oligodendroglia, choroid plexus epithelium, vascular endothelium, meningeal cells, fibroblasts, and other mesenchymal elements. The factors responsible for the consistent results obtained in routinely processed tumor tissues are the following: (a) The GFA protein antiserum usually employed in the procedure is highly immunospecific, its monospecificity having been verified by immunodiffusion, immunoelectrophoresis, and electrophoresis of the immunoprecipitates; (b) GFA protein is strongly immunogenic, considerably more than any other antigenic determinant that might be expected to act as contaminant even in well purified GFA protein preparations; (c) contamination by other antigen determinants, particularly tubulin, is of little practical importance in the application of the immunoperoxidase reaction; (d) the antigenicity of GFA protein appears remarkably resistant to routine formalin fixation and to the paraffin-embedding process; (e) the PAP technic favors the use of antisera at high dilutions (ranging from 1 in 100 to 1 in 1000), therefore resulting in a marked increase of both sensitivity and specificity of the staining procedure; (f) background staining is considerably reduced by preliminary treatment of tissue sections with normal serum in order to block nonspecific immunoglobulin-binding sites.

Interpretative Problems. The major interpretative difficulties raised by this method are as follows:

(1) The problem whether the positively staining astrocytes in a tumor are reactive or neoplastic. The difficulty is not a new one in the diagnostic interpretation of cerebral tumors, but it is considerably magnified by the technic by virtue of its remarkable sensitivity combined with its great specificity for glial-fiber-forming cells. Consequently, if only one or very few cells for which the stain is specific are present in the section, these cells will stain intensely, and the microscopic picture will reveal, to a degree to which conventional preparations have not accustomed us, the presence of astrocytes in the central portions of metastatic nonglial neoplasms, of invasive mesenchymal tumors such as malignant meningiomas or sarcomas, in primitive neuroepithelial tumors, in reticulum-cell sarcomas-microgliomas, and in capillary hemangioblastomas. Light counterstaining of the sections with hematoxylin after the immunoperoxidase reaction is of considerable help in these instances, as the counterstain does not impair visualization of the brown diaminobenzidine reaction product and often seems to enhance it. Nuclear staining of course permits more precise identification of neoplastic cells as well as a better comparison of adjacent serial tissue sections subjected to different staining procedures.

(2) The interpretation of a negative staining reaction in glial tumors. False negative reactions may occur as a result of delayed or improper processing of the tissue, or from delayed or excessive fixation. However, in a tumor that is clearly of glial origin, a negative stain means that either the neoplastic cells do not belong to the astrocytic series, or, if they do, that they are either too primitive or too anaplastic to synthesize the protein.

(3) The possibility of a false positive staining reaction. Until recently it was widely accepted that, in the presence of appropriate negative controls (that is, if

serial sections from the same block preliminarily incubated with preimmunization serum or with absorbed hyperimmune serum remain unstained following the PAP reaction) and provided the sections have been previously treated with hydrogen peroxide in anhydrous methanol so as to block the activity of any endogenous peroxidase, positive PAP staining localized to the cell cytoplasm and processes unequivocally indicated the presence of GFA protein in these cells and consequently these cells should be interpreted as glial cells capable of forming glia-specific fibers. It is, however, apparent from our recent observations in capillary hemangioblastomas (see below) that when intensive reactive gliosis is present in the vicinity the possibility of GFA protein uptake by neoplastic or nonneoplastic cells should be considered as an alternative interpretation of some of the immunoperoxidase findings. Systematic investigations on whether GFA protein uptake by macrophages occurs in necrotic areas of the brain, including tumors, are so far lacking. It is possible that the staining reaction in macrophages might remain weak because of the proteolytic activity that normally takes place in those cells. Radioimmune assays of GFA protein in cerebrospinal fluid have shown raised levels of the protein in various intracranial conditions, especially in astrocytoma and glioblastoma (Hayakawa et al.). The highest reported levels occurred with glioblastomas: this could reflect the considerable necrosis characteristic of that tumor, a suggestion reinforced by the observation that the cerebrospinal fluid protein level increased steeply after surgical procedures that caused a large amount of brain or tumor tissue destruction. This might indicate that GFA protein can be released from glial cells in the presence of brain tissue destruction.

We certainly have at our disposal a morphologic diagnostic tool of considerable value and on which great reliance can be placed for the identification of glial tumor cells. However, despite the several new contributions that this technic has made to the resolution of cytologic diagnostic problems, caution is needed before placing sole reliance on the immunoperoxidase method to the exclusion of all other histologic evidence.

Recent Observations and Possible Implications. In addition to establishing the correct diagnosis in many examples of central nervous system tumors that raised difficult interpretative problems because of their atypical cytologic features, their unusual histologic pattern, or their localization outside the parenchyma of the central nervous system, the PAP method for GFA protein has played a major role in the following studies of nervous system neoplasms:

(1) The investigation of pineal parenchymal tumors (pineocytomas) that exhibit divergent differentiation along glial and neuronal lines (Herrick and Rubinstein) and the identification of occasional primary astrocytomas of the pineal (Papasozomenos and Shapiro).

(2) The identification of a distinctive form of superficial supratentorial astrocytoma occurring in young subjects, with relatively favorable prognosis and containing variable amounts of lipid in the cytoplasm of the tumor cells. The neoplasm, in which the cells are often surrounded by reticulin fibers, was originally interpreted as a meningocerebral fibroxanthoma and has since been redefined as a clinicohistopathologic tumor entity of astrocytic

nature for which the term "pleomorphic xanthoastrocytoma" was suggested (Kepes et al., 1979b). The presence of pericellular reticulin fibers is explained partly by the largely leptomeningeal localization of the neoplasm, partly also by the hypothesis that it is derived from subpial cortical astrocytes, which are known to be covered by a basal lamina at their interface with the leptomeninx.

(3) The recognition that malignant gliomas, including glioblastomas, may occasionally be heavily lipidized, in which case the vacuolated foamy appearance of the tumor cells (pl. XVI-I) may obscure their glial nature (Kepes and Rubinstein).

(4) In regard to the intraventricular giant cell tumor typically associated with tuberous sclerosis and designated on page 40 of the Fascicle as a subependymal giant cell astrocytoma (figs. 22 and 23), doubt has been cast on the astrocytic nature of the neoplastic cells in a report by Stefansson and Wollmann (1980), who found that these cells showed complete absence of staining for GFA protein. The same workers subsequently observed (Stefansson and Wollmann, 1981) that the cells were intensely positive for a neuronal-specific protein, 14-3-2, thus suggesting that the giant subependymal tumors may be of neuronal rather than of astrocytic origin. Duffy and associates found that in this tumor GFA protein was restricted in most cells to a narrow peripheral zone. Our own results on a few cases so far have been inconsistent. In some examples, the tumor cells appear entirely negative for GFA protein. In others, varying numbers of cells range from moderately to strongly positive. It is possible that this tumor, whose features are so characteristic in conventional stains, may constitute a more heterogeneous entity than is at first apparent. More examples need to be studied to resolve this controversial problem.

(5) Because of the occasional diagnostic difficulties that may occur in distinguishing choroid plexus papillomas from papillary ependymomas (see pp. 125 and 261 of the Fascicle), the presence of GFA protein has been investigated in choroid plexus papillomas (Rubinstein and Brucher). Positivity for the protein was found focally in the epithelial tumor cells of 9 of 22 tumors (pl. XVI-H). In 6 of these 9 tumors, intracellular fibrils were found in a small number of elongated epithelial cells with the PTAH and/or the Masson trichrome stains. In all these six tumors the GFA protein-positive cells were considerably more numerous than the cells containing fibrils. These findings have been interpreted as suggesting that focal ependymal differentiation is occasionally expressed in choroid plexus papillomas, an observation that is consistent with the origin of the choroid plexus from primitive ventricular neuroepithelium.

(6) The finding by Kepes and associates (1979a), in 13 cases of hemangioblastomas of the central nervous system examined with the PAP technic, of variable numbers of GFA protein-positive cells in seven tumors, reopened once more the debate on the histogenesis of the stromal cells in capillary hemangioblastomas (see pp. 235 and 239 of the Fascicle). From their study, Kepes and colleagues concluded that these cells form a heterogeneous group that include astrocytes as well as other elements and that they resemble each other in traditional stains because of the "equalizing effect" of cell lipidization. In a subsequent study in which 39 hemangioblastomas were studied by the immunoperoxidase method

PLATE XVI

IMMUNOPEROXIDASE STAINING FOR GLIAL FIBRILLARY ACIDIC (GFA) PROTEIN

(All illustrated examples, except Plate XVI-C, were lightly counterstained with hematoxylin.)

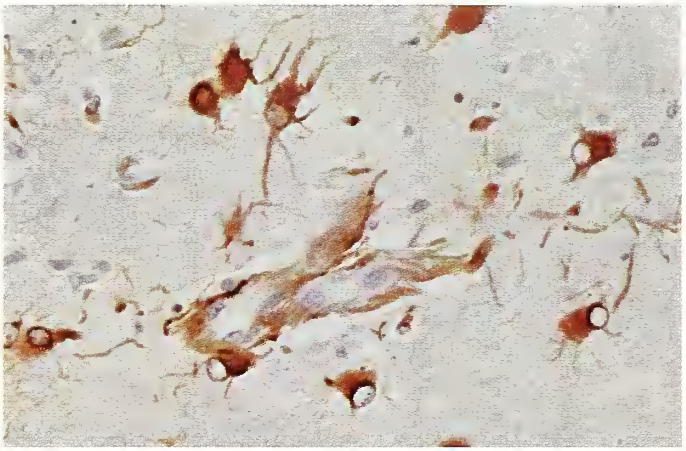

A. REACTIVE ASTROCYTES

The reactive astrocytes in this field of cerebral cortex adjacent to subarachnoid tumor are strongly positive. Note negative staining of all the cell nuclei. Positively staining astrocytic processes enwrap the wall of a capillary blood vessel (center), which is lined by negatively staining endothelial cells. X200.

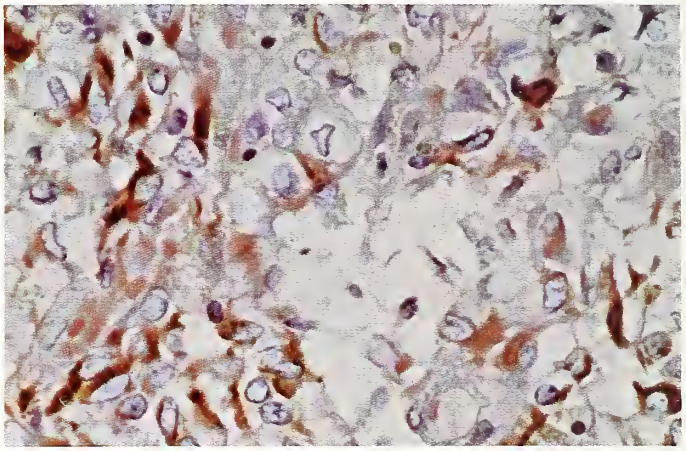

B. MALIGNANT ASTROCYTOMA

This anaplastic astrocytoma shows variable positivity of the tumor cells for GFA protein. The nuclei do not stain. X200.

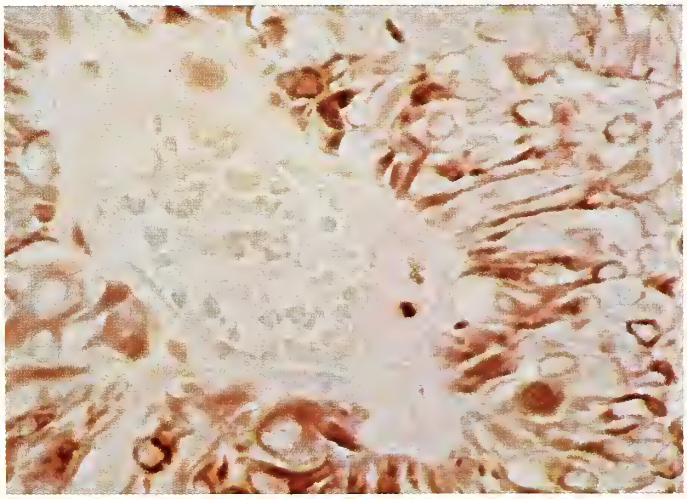

C. ASTROBLASTOMA

Positively staining astroblasts have their cell processes directed to the outer wall of a central, negatively stained blood vessel. X320.

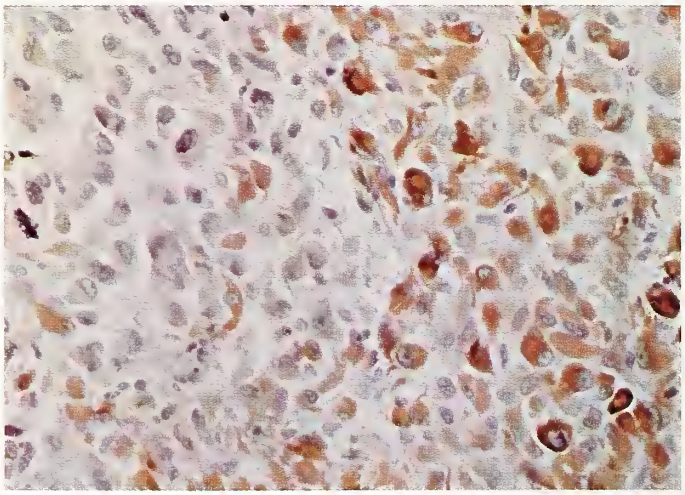

D. MIXED ASTROCYTOMA AND OLIGODENDROGLIOMA

This field shows a group of cells that are frequently GFA-protein positive, adjacent to a group of cells that are largely negative. X200.

E. MIXED GLIOBLASTOMA AND FIBROSARCOMA (GLIOSARCOMA)

This mixed glioblastoma and fibrosarcoma demonstrates the contrast obtained by GFA protein-positive areas (glioblastoma) adjacent to largely negative areas (fibrosarcoma). An occasional GFA protein-positive glial tumor cell is trapped in the fibrosarcomatous areas. X80.

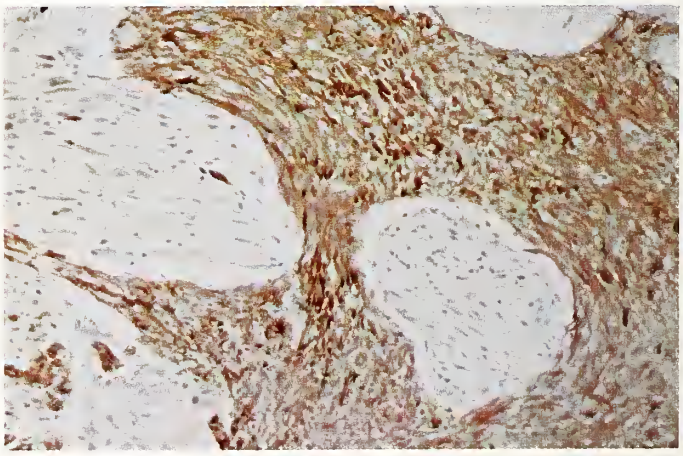

PLATE XVI

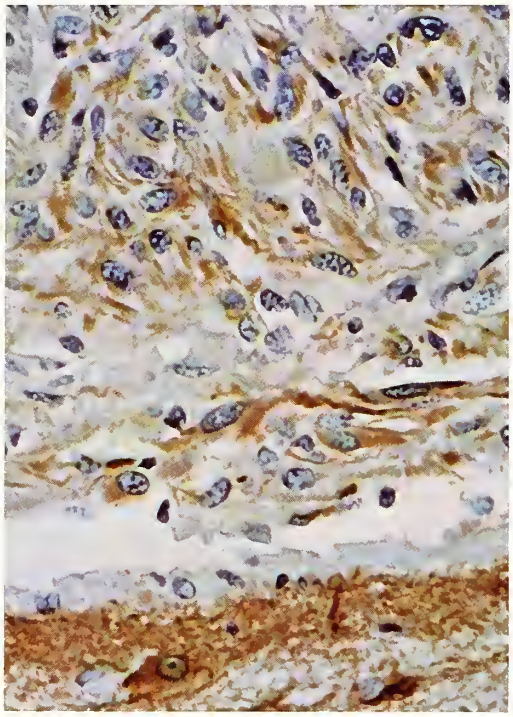

F. ASTROCYTOMA INVADING THE LEPTOMENINGES

This field represents spindle shaped GFA protein-positive astrocytes invading the leptomeninges (upper three quarters). The lower quarter of the field shows an intensively positive band of subpial glia separated from subarachnoid tumor by a thin layer of GFA protein-negative pia-arachnoidal cells. X360.

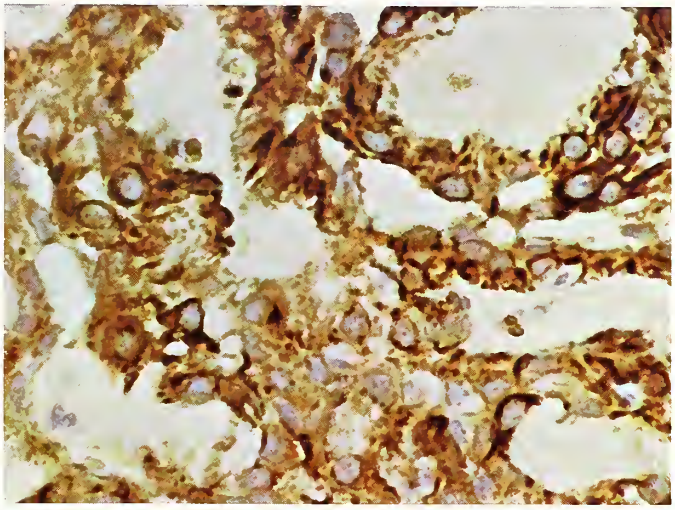

G. MYXOPAPILLARY EPENDYMOMA

The cells in this myxopapillary ependymoma originating from the filum terminale show intense positivity for GFA protein, contrasted with the complete negativity of the central thickened and hyalinized vascular cores (compare with figure 124). X250.

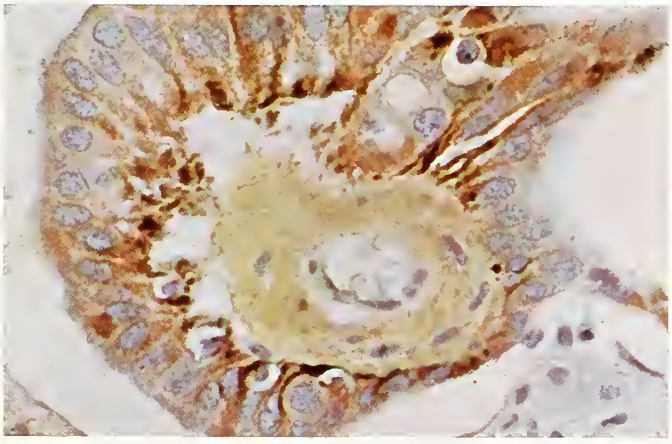

H. CHOROID PLEXUS PAPILLOMA

A number of columnar epithelial cells show positivity for GFA protein, which is represented as a thick streak most prominent along the base of the cells. The expression of GFA protein in epithelial cells of choroid plexus papillomas is interpreted as representing focal ependymal differentiation. X320.

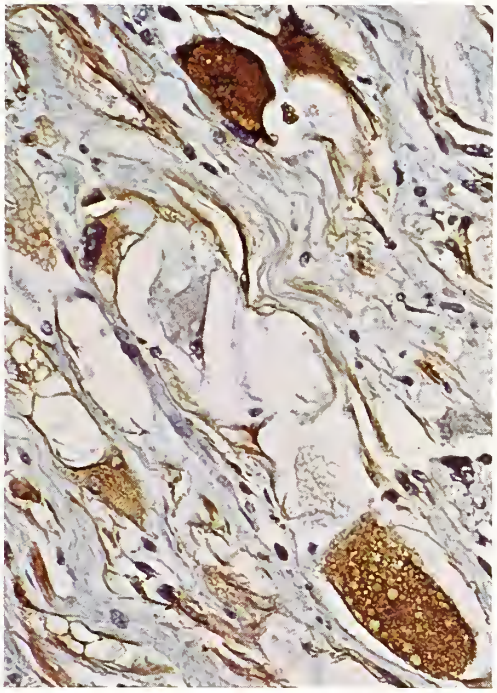

I. LIPIDIZED (FOAMY) GLIOBLASTOMA CELLS

In this glioblastoma, a number of malignant glial cells show a vacuolated foamy cytoplasm, as well as positivity for GFA protein. The droplets illustrated in this example had varying degrees of positivity for fat in frozen section. X200.

Table VII

IMMUNOPEROXIDASE REACTION OF GFA PROTEIN IN NONNEOPLASTIC AND NEOPLASTIC CELLS OF THE CENTRAL NERVOUS SYSTEM

GFA protein-positive

I. Nonneoplastic

1. Normal fibrillary astrocytes
2. Normal protoplasmic astrocytes (?)
3. Bergmann glial cells
4. Reactive astrocytes
5. Reactive fibrillated ependymal cells
6. Fetal ependymal cells (transient stage)

II. Neoplastic

A. Astrocytic

1. Astrocytomas
2. Astroblastomas
3. Astrocytic cells of
   mixed gliomas
   gangliogliomas
   mixed gliomas and sarcomas
4. Differentiated astrocytic cells in
   anaplastic astrocytomas
   glioblastomas
5. Differentiated astrocytic cells in
   pineocytomas
   medulloblastomas

B. Nonastrocytic

1. Ependymomas (most)
2. Subependymomas
3. Choroid plexus papillomas (some cells only)
4. Stromal cells of capillary hemangioblastomas (some cells only)

GFA protein-negative

I. Nonneoplastic

1. Oligodendrocytes
2. Normal adult ependymal cells
3. Ganglion cells
4. Normal choroid plexus epithelial cells
5. Pineocytes
6. Endothelial cells
7. Arachnoidal cells
8. Fibroblasts
9. Microglia & macrophages (usually)

II. Neoplastic

1. Anaplastic glial cells
2. Primitive (embryonal) neuroepithelial cells
3. Oligodendrogliomas
4. Ependymomas (some)
5. Choroid plexus papillomas (most cells)
6. Pineocytomas
7. Meningiomas
8. Sarcomas
9. Capillary hemangioblastomas (most cells)
10. Malignant lymphomas (reticulum cell sarcomas-microgliomas)
11. Metastatic tumors

(Deck and Rubinstein), the observations of Kepes and associates were confirmed. In 6 of these tumors, representing both the reticular and the cellular variants of hemangioblastoma, GFA protein-positive stromal cells were found, chiefly at the periphery of the neoplasm. All these tumors were surrounded by dense reactive gliosis. Moreover, reactive gliosis in the form of trapped GFA protein-positive astrocytes or astrocytic cell processes penetrated the margins of all the neuraxial tumors and was especially prominent in those recurring after surgical excision and in patients with a long history of neoplasm. After considering the hypotheses that might account for the presence of GFA protein-positive stromal cells, we concluded that these cells are capable of taking up extracellular GFA protein derived from adjacent reactive astrocytes, a conclusion that was most consistent with the collective evidence provided by the various histologic observations. The implications are important, as they suggest that the presence of GFA protein in the cytoplasm of a cell does not necessarily establish that the cell is glial. The possibility of uptake of GFA protein by nonglial cells may therefore have to be considered if dense gliosis is present in the vicinity.

Table VII summarizes the results obtained to date on the immunoperoxidase reaction for GFA protein in nonneoplastic and neoplastic cells of the central nervous system.

References

Bignami, A., Dahl, D., and Rueger, D. C. Glial Fibrillary Acid Protein (GFA) in Normal Neural Cells and in Pathological Conditions, pp. 285-310. In: Advances in Cellular Neurobiology, Vol. 1. Fedoroff, S. and Hertz, L. (Eds.). New York: Academic Press, 1980.

DeArmond, S. J., Eng., L. F., and Rubinstein, L. J. The application of glial fibrillary acidic (GFA) protein immunohistochemistry in neurooncology. A progress report. Pathol. Res. Pract. 168:374-394, 1980.

Deck, J. H. N. and Rubinstein, L. J. Glial fibrillary acidic protein in stromal cells of some capillary hemangioblastomas: significance and possible implications of an immunoperoxidase study. Acta Neuropathol. 54:173-181, 1981.

Duffy, P. E., Huang, Y-Y., Rapport, M. M., and Graf, L. Glial fibrillary acidic protein in giant cell tumors of brain and other gliomas. A possible relationship to malignancy, differentiation, and pleomorphism of glia. Acta Neuropathol. 52:51-57, 1980.

Eng, L. F. The Glial Fibrillary Acidic (GFA) Protein, pp. 85-117. In: Proteins of the Nervous System, 2d. Ed. Bradshaw, R. A. and Schneider, D. M. (Eds.). New York: Raven Press, 1980.

_____ and Rubinstein, L. J. Contribution of immunohistochemistry to diagnostic problems of human cerebral tumors. J. Histochem. Cytochem. 26:513-522, 1978.

Hayakawa, T., Morimoto, K., Ushio, Y., Mori, T., Yoshimine, T., Myoga, A., and Mogami, H. Levels of astroprotein (an astrocyte-specific cerebroprotein) in cerebrospinal fluid of patients with brain tumors. J. Neurosurg. 52:229-233, 1980.

Herrick, M. K. and Rubinstein, L. J. The cytological differentiating potential of pineal parenchymal neoplasms (true pinealomas). A clinicopathological study of 28 tumours. Brain 102:289-320, 1979.

Kepes, J. J. and Rubinstein, L. J. Malignant gliomas with heavily lipidized (foamy) tumor cells: a report of three cases with immunoperoxidase study. Cancer 47:2451-2459, 1981.

_____, Rengachary, S. S., and Lee, S. H. Astrocytes in hemangioblastomas of the central nervous system and their relationship to stromal cells. Acta Neuropathol. 47:99-104, 1979a.

_____, Rubinstein, L. J., and Eng., L. F. Pleomorphic xanthoastrocytoma: A distinctive meningocerebral glioma of young subjects with relatively favorable prognosis. A study of 12 cases. Cancer 44:1839-1852, 1979b.

Mannoji, H., Takeshita, I., Fukui, M., Ohta, M., and Kitamura, K. Glial fibrillary acidic protein in medulloblastoma. Acta Neuropathol. 55:63-69, 1981.

Palmer, J. O., Kasselberg, A. G., and Netsky, M. G. Differentiation of medulloblastoma. Studies including immunohistochemical localization of glial fibrillary acidic protein. J. Neurosurg. 55:161-169, 1981.

Papasozomenos, S. and Shapiro, S. Pineal astrocytoma: report of a case confined to the epiphysis, with immunocytochemical and electron microscopic study. Cancer 47:99-103, 1981.

Rubinstein, L. J. and Brucher, J. M. Focal ependymal differentiation in choroid plexus papillomas. An immunoperoxidase study. Acta Neuropathol. 53:29-33, 1981.

Stefansson, K. and Wollmann, R. Distribution of glial fibrillary acidic protein in central nervous system lesions of tuberous sclerosis. Acta Neuropathol. 52:135-140, 1980.

_____ and Wollmann, R. Distribution of the neuronal specific protein, 14-3-2, in central nervous system lesions of tuberous sclerosis. Acta Neuropathol. 53:113-117, 1981.

Sternberger, L. A. Immunocytochemistry, 2d. ed. New York: John Wiley & Sons, 1979.

Velasco, M. E., Dahl, D., Roessmann, U., and Gambetti, P. Immunohistochemical localization of glial fibrillary acidic protein in human glial neoplasms. Cancer 45:484-494, 1980.

INDEX

Adenovirus type 12 human
  tumors, induction, animals, S-4, S-5
Alkylating agents
  nitrosoureas, induction of animal tumors, S-1, S-2
  organ specificity, S-1
Anaplasia
  schwannomas, peripheral nervous system, S-3
Animals
  models, neurooncogenesis, S-2
Astroblastomas
  stains, immunoperoxidase, for GFA protein, S-22, **S-26**
Astrocytes
  pineocytomas, S-17
  stains, immunoperoxidase, for GFA protein, S-22, S-23, **S-26**
Astrocytomas
  induction, viral, S-4
  invading leptomeninges, stain for GFA protein, **S-27**
  malignant, stain for GFA protein, **S-26**
  mixed, stain for GFA protein, **S-26**
  stains, immunoperoxidase, S-22
  supratentorial, diagnosis, S-24

C-6 glioma
  tumor cell line, S-3
Carcinogenesis
  transplacental, rats, S-2
Cloning
  cell lines, pure, production, S-3
Craniospinal hemangiomas, see Meningiomas, angioblastic

Diagnosis
  stains, immunoperoxidase, for GFA protein, S-21—S-25, **S-26, S-27**, S-28, S-29
Differentiation
  pineocytomas
    astrocytic, S-17, S-20
    divergent, S-17
    ganglionic, **S-18, S-19**
    neuronal, S-17, S-18, S-20
  tumors, pineal parenchymal, S-15
DNA tumor viruses
  induction, neural tumors, S-4
Dosage
  ethylnitrosourea, tumor induction, S-2, S-3

Ependymonas
  myxopapillary, stains, for GFA protein, S-22, **S-27**
  papillary, diagnosis, S-25

Ethylnitrosourea
  dosage, tumor induction, S-2, S-3
  schwannomas, malignant, induction, chronologic pattern, S-2
  tumors, neural, induction, S-1

Fibrosarcomas
  stains, for GFA protein, S-22, **S-26**

GFA protein, see Glial fibrillary acidic protein
Giant cell tumors
  intraventricular, diagnosis, S-25
Glial fibrillary acidic protein
  immunoperoxidase stains, technic, S-21—S-29
  peroxidase-antiperoxidase immune chemistry, S-21
  stains, **S-26, S-27**
Glioblastomas
  diagnosis, S-25
  induction, viral, S-4
  lipidized cells, S-25, **S-27**
  stains, for GFA protein, S-22, **S-26**
Glioma cells
  stains, immunoperoxidase, S-22
Gliomas
  brain, and spinal cord, S-3
  C-6 cell line, S-3
  human, transplantation, to athymic nude mice, S-6
  induction time, S-2
  multiple periventricular subependymal, S-2
Gliosarcomas, see Fibrosarcomas

Hemangioblastomas
  diagnosis, S-25, S-29
Hemangiopericytomas
  nomenclature, S-9—S-12
Hemangiopericytomas, craniospinal, see Meningiomas, angioblastic

Immunoperoxidase stains
  for GFA protein, S-21—S-24, **S-26, S-27**
  reactions, GFA protein, positive and negative, S-28

Mechanism of action
  nitrosoureas, carcinogenesis, S-2

Medulloblastomas
cerebellar
induction, hamsters, by human polygoma virus, S-4
mice, S-3
stains, immunoperoxidase, S-22
Mengiomas
papillary variant, S-13
Mengiomas, angioblastic
hemangioblastic, S-11
hemangiopericytic, S-9, **S-10**, S-11, **S-11**
nomenclature, S-9—S-12
Methodology
tumors, experimental induction, animals, S-1
Methylnitrosourea
tumors, neural, induction, S-1
Mice
athymic, nude, transplantation of human gliomas, S-6
Microscopy
pineoblastomas, S-16, **S-16**
Microscopy, electron
menangiomas, angioblastic, S-9, **S-10**, **S-11**, S-12
pineocytomas, S-18, **S-18**, S-19, **S-19**
Models
mice, athymic, nude, transplantation of human gliomas, S-6
teratomas, transplantable, mice, S-5, S-6
tumors
embryonal, S-5
experimental, animals, S-1

Neuroblastomas
intracerebral, induction by human adenovirus type 12, S-4
visceral, induction, S-5
Neurocarcinogens
malignancy, induction, S-2
neurooncology, S-1
neurotropic carcinogenic agents, S-1
nitrosoureas, rats, S-2—S-4
oncogenic viruses, S-5
N-Nitroso compounds
resorptive, induction of neural tumors, S-1
Nitrosoureas
ethylnitrosourea, induction of neural tumors, S-1
methylnitrosourea, induction of neural tumors, S-1
neurocarcinogenicity, rats, S-2
Nomenclature
hemangiopericytomas, S-9—S-12
menangiomas, angioblastic, S-9—S-12
pineoblastomas, S-17
pineocytomas, S-17

Oligodendrogliomas
induction, by nitrosoureas, S-3
stains, for GFA protein, **S-26**
Organ specificity
N-nitroso compounds, induction of neural tumors, S-1

Papillomas
choroid plexus
diagnosis, S-25
GFA protein stain, **S-27**
Peripheral nervous system
schwannomas, S-3
Peroxidase-antiperoxidase immunohistochemistry
diagnosis, CNS tumors, S-21
Pineoblastomas
identification, silver carbonate technic, S-15
microscopy, S-16, **S-16**
Pineocytomas
diagnosis, S-24
induction, with oncogenic virus, S-5
microscopy, electron, ganglionic differentiation, S-18, **S-18**, **S-19**
stains, silver carbonate technic, S-15
Polyoma virus
human, JC strain, tumor induction, animals, S-4, S-5

Retinoblastomas
induction, by human adenovirus type 12, S-4
RNA tumor viruses
induction, neural tumors, S-4
Rous avian sarcoma virus
induction, neural tumors, S-4

Schwannomas
anaplasia, peripheral nervous system, S-3
differentiated, following methylnitrosourea, S-3
induction, chronologic pattern following ethylnitrosourea, S-2
peripheral nervous system, S-3
Spinal nerve roots
schwannomas, site of induction, rats, S-3
Stains
peroxidase-antiperoxidase immunohistochemistry, CNS tumors, S-21, **S-26**, **S-27**

Teratoma OTT-6050
models, neuronal differentiation, S-5, S-6
Teratomas
transplantable, mouse models, S-5

Transplantation
gliomas, human, to athymic nude mice, S-6
teratomas, mouse models, S-5
Trigeminal nerve root
schwannomas, site of induction, rats, S-3
Tumors
cell lines, pure, S-3
diagnosis, immunoperoxidase method for GFA protein, S-21
embryonal, S-5
experimental, animals, S-1, S-4—S-6
gliomas, induction, S-3
induction
chronologic patterns, S-2
viral, S-4, S-5
medulloblastomas, cerebellar, induction, mice, S-3
mixed cell type, in nitrosourea induction, S-3
neural, induction, S-1, S-4
neuronal, induction, rare, S-3
oligodendrogliomas, induction, by nitrosoureas, S-3
Tumors (continued)
pineal parenchymal, S-15
schwannomas, peripheral nervous system, induction, S-3
sites, schwannomas, S-3
transplantation, S-5, S-6

Viruses, oncogenic
adenovirus type 12 human, S-4
DNA, S-4
polyoma, human, JC strain, S-4, S-5
RNA, S-4
Rous avian sarcoma, S-4
specificity, S-5
tumors, neural, induction, S-4, S-5

Xanthoastrocytomas
pleomorphic, S-25

PRINTED BY THE ARMED FORCES INSTITUTE OF PATHOLOGY

PROFESSIONAL NOTES AND FINDINGS

DATE DUE

GAYLORD PRINTED IN U.S.A.

NIH LIBRARY
4 0144 4326

NIH Library, Building 10
National Institutes of Health
Bethesda, Md. 20205

LIBRARY
NIH
Amazing Research.
Amazing Help.

http://nihlibrary.nih.gov

10 Center Drive
Bethesda, MD 20892-1150
301-496-1080

NIH LIBRARY
3 1496 00195 0834

MAR 17 1987